

TRAHUNR

ISSN: 2181-0990
DOI: 10.26739/2181-0990

**JOURNAL OF
REPRODUCTIVE
HEALTH AND
URO-NEPHROLOGY
RESEARCH**



TADQIQOT.UZ

VOLUME 1, ISSUE 1

2020

МИНИСТЕРСТВО ЗДРАВООХРАНЕНИЯ
РЕСПУБЛИКИ УЗБЕКИСТАН

Журнал репродуктивного здоровья и уро-
нефрологических исследований

JOURNAL OF REPRODUCTIVE HEALTH AND URO-NEPHROLOGY RESEARCH

Главный редактор- Б.Б. НЕГМАДЖАНОВ

Учредитель:

Самаркандский государственный
медицинский институт

Tadqiqot.uz

Ежеквартальный
научно-практический
журнал

ISSN: 2181-0990
DOI 10.26739/2181-0990

N^o 1
2020

**Главный редактор:
Chief Editor:**

Негмаджанов Баходур Болтаевич
доктор медицинских наук, профессор, заведующий
кафедрой Акушерства и гинекологии №2
Самаркандского Государственного Медицинского
Института

**Заместитель главного редактора:
Deputy Chief Editor:**

Каттаходжаева Махмуда Хамдамовна
доктор медицинских наук, профессор
Кафедры акушерства и гинекологии
Ташкентского Государственного стоматологического
института

**ЧЛЕНЫ РЕДАКЦИОННОЙ КОЛЛЕГИИ:
MEMBERS OF THE EDITORIAL BOARD:**

Луис Альфондо де ла Фуэнте Эрнандес
профессор, Медицинский директор IEFertility, член
Европейского общества репродукции человека и эмбриологии
(Prof. Medical Director of the Instituto Europeo de Fertilidad.
Madrid (Spain)

Ramašauskaitė Diana
профессор, руководитель центра акушерства и гинекологии в
больнице Вильнюсского университета Santaros klinikos (Prof.
Clinic of Obstetrics and Gynecology Vilnius University Faculty of
Medicine (Литва)

Аюпова Фариди Мирзаевна
Доктор медицинских наук, профессор, заведующая
кафедрой Акушерства и гинекологии №1
Ташкентской Медицинской Академии.

Зокирова Нодира Исламовна
Доктор медицинских наук, профессор кафедры
акушерства и гинекологии №1, Самаркандского
Государственного Медицинского Института

Кадыров Зиёратшо Абдуллоевич
Доктор медицинских наук, профессор заведующий
кафедрой Эндоскопической урологии факультета
непрерывного медицинского образования
медицинского института РУДН, (Россия).

Негматуллаева Мастура Нуруллаевна
Доктор медицинских наук, профессор
кафедры акушерства и гинекологии №2,
Бухарского Медицинского института.

Окулов Алексей Борисович
Доктор медицинских наук., профессор,
андро-гинеколог, главный научный сотрудник кафедры
Детской хирургии педиатрического факультета РМАНПО,
профессор кафедры медицинской репродуктологии и
хирургии Московского государственного
медико-стоматологического университета (Россия).

Махмудова Севара Эркиновна
ассистент кафедры Акушерства и гинекологии факультета
последипломного образования Самаркандского Государственного
Медицинского Института (**ответственный секретарь**)

**ЧЛЕНЫ РЕДАКЦИОННОГО СОВЕТА:
MEMBERS OF THE EDITORIAL BOARD:**

Boris Chertin
MD Chairman, Departments of Urology & Pediatric Urology,
Shaare Zedek Medical Center, Clinical Professor in Surgery/
Urology, Faculty of Medicine, Hebrew University, Jerusalem (Israel).
Председатель кафедры урологии и детской урологии,
Медицинский центр Шааре-Зедек, Клинический профессор
хирургии/урологии, медицинский факультет, Иерусалим, Израиль

Fisun Vural
Doçent Bilimleri Üniversitesi, Haydarpaşa Numune Eğitim ve
Araştırma Hastanesi Kadın Hastalıkları ve Doğum Kliniği İdari ve
Eğitim Sorumlusu (Доцент Dr.Фисун Вурал Университет
медицинских наук. Репродуктолог. Ведущий специалист по
вспомогательной репродуктивной технологии (Турция)

Melike Betül Ögütmen
SBÜ Haydarpaşa Numune SUAM Nefroloji
Kliniği idari ve Eğitim Sorumlusu
(Доцент. Dr. Малике Бетул Угутмен.
Нефролог. Университет медицинских наук (Турция)

Аллазов Салах Аллазович
доктор медицинских наук, профессор
кафедры урологии, Самаркандского
Государственного Медицинского Института

Ахмеджанова Наргиза Исмаиловна
доктор медицинских наук,
Самаркандского Государственного
Медицинского Института, нефролог

Локшин Вячеслав Нотанович
акушер-гинеколог, репродуктолог,
доктор медицинских наук, профессор,
президент Казахстанской ассоциации
репродуктивной медицины (Казахстан).

Никольская Ирина Георгиевна
Доктор медицинских наук, профессор ГБУ МО
МОНИАГ. Ученый секретарь научного совета (Россия).

Шалина Раиса Ивановна
Доктор медицинских наук, профессор кафедры
акушерства и гинекологии педиатрического факультета
РНМУ им.Н.И.Пирогова (Россия).

Page Maker | Верстка: Хуршид Мирзахмедов

Контакт редакций журналов. www.tadqiqot.uz
ООО Tadqiqot город Ташкент,
улица Амира Темура пр.1, дом-2.
Web: <http://www.tadqiqot.uz/>; Email: info@tadqiqot.uz
Телефон: +998 (94) 404-0000

Editorial staff of the journals of www.tadqiqot.uz
Tadqiqot LLC the city of Tashkent,
Amir Temur Street pr.1, House 2.
Web: <http://www.tadqiqot.uz/>; Email: info@tadqiqot.uz
Phone: (+998-94) 404-0000

СОДЕРЖАНИЕ/CONTENT

Обращение ректора Самаркандского государственного медицинского института д.м.н, профессора Ж.А. Ризаева и главного редактора д.м.н., профессора Б.Б. Негмаджанова.....6

Ramašauskaitė Diana. Best wishes to the new journal.....7

ОБЗОРНЫЕ СТАТЬИ

1. Ахмедов Я.А.

ОСНОВЫ ЛУЧЕВОЙ ДИАГНОСТИКИ ЗАБОЛЕВАНИЙ МОЧЕВЫДЕЛИТЕЛЬНОЙ СИСТЕМЫ У ДЕТЕЙ (ОБЗОР).....8

2. Аюпова Ф.М., Солиева У.Х., Миродилова Ф.Б.

ПРИМЕНЕНИЕ МИКРОНИЗИРОВАННОГО ПРОГЕСТЕРОНА В КОМПЛЕКСЕ ПРОФИЛАКТИКИ И ЛЕЧЕНИЯ НЕВЫНАШИВАНИЯ БЕРЕМЕННОСТИ (ОБЗОР).....13

3. Кадыров З.А., Фаниев М.Д., Сергеев В.В.

СОВРЕМЕННОЕ СОСТОЯНИЕ ПРОБЛЕМЫ ОСТРОГО ГЕСТАЦИОННОГО ПИЕЛОНЕФРИТА (ОБЗОР).....17

4. Каттоходжаева М.Х., Сулейманова Н.Ж., Амонова З.Д., Шакирова Н.Г.

АКТУАЛЬНОСТЬ ПРОБЛЕМЫ ГЕНИТАЛЬНОЙ ПАПИЛЛОМАВИРУСНОЙ ИНФЕКЦИИ И РАК ШЕЙКИ МАТКИ. СТРАТЕГИИ ПРОФИЛАКТИКИ (ОБЗОР).....22

5. Нигматова Г.М., Агзамова М

СОВРЕМЕННОЕ СОСТОЯНИЕ ЭТИОПАТОГЕНЕЗЕ ПРЕЖДЕВРЕМЕННЫХ РОДОВ (ОБЗОР).....29

6. Agababyan L.R., Makhmudova S.E.

COMPARISON OF PLACENTAL PATHOLOGY BETWEEN SEVERE PREECLAMPSIA AND HELLP SYNDROME (REVIEW).....34

7. Ashurova U.A., Abdullaeva L.M., Klychev S.I., Ahmedova A.T.

SURGICAL APPROACH TO THE TREATMENT OF ENDOMETRIOID OVARIAN CYSTS IN PATIENT WITH INFERTILITY: «FOR» AND «AGAINST» (REVIEW).....38

8. Nasirova Z.A.

REPRODUCTIVE BEHAVIOR OF WOMEN AFTER CESAREAN SECTION (REVIEW).....42

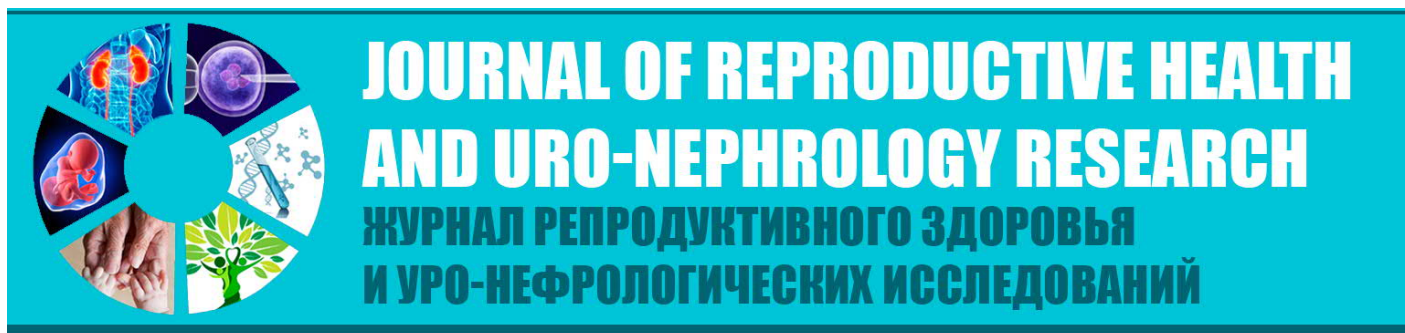ОРИГИНАЛЬНЫЕ СТАТЬИ

9. Ахмедова А.Т.


ВЛИЯНИЕ ФИТОГОРМОНОВ НА КАЧЕСТВО ЖИЗНИ ЖЕНЩИН С ЭНДОМЕТРИОЗОМ В ПЕРИОДЕ ПЕРИМЕНОПАУЗЫ.....46

10. Гарифулина Л.М., Гайибов Н.С.

СОСТОЯНИЕ ПОЧЕК У ДЕТЕЙ С ЭКЗОГЕННО-КОНСТИТУЦИОНАЛЬНЫМ ОЖИРЕНИЕМ.....50



УДК:618.177:618.145+618.11-006-089

Ashurova Umida AlisherovnaDoctor of Philosophy,
Republican Specialized Scientific and Practical Medical Center
for Obstetrics and Gynecology,
Tashkent, Uzbekistan**Abdullayeva Lola Mirzatullayevna**Doctor of medical science,
Republican Specialized Scientific and Practical Medical Center
for Obstetrics and Gynecology,
Tashkent, Uzbekistan**Klychev Spartak Ilhomovich**Doctor of Medical Sciences, Professor
Republican Specialized Scientific and Practical Medical Center
for Obstetrics and Gynecology,
Tashkent, Uzbekistan**Ahmedova Aziza Tairovna**Assistant at Samarkand State Medical Institute
Departments of Obstetrics and Gynecology,
of the Faculty of Postgraduate Education,
Samarkand, Uzbekistan.**SURGICAL APPROACH TO THE TREATMENT OF ENDOMETRIOID OVARIAN CYSTS IN PATIENT WITH INFERTILITY:
«FOR» AND «AGAINST» (REVIEW)****For citation:** Ashurova Umida Alisherovna, Abdullayeva Lola Mirzatullayevna, Klychev Spartak Ilhomovich, Ahmedova Aziza Tairovna, Surgical approach to the treatment of endometrioid ovarian cysts in patient with infertility: «for» and «against» (review), Journal of reproductive health and uro-nephrology research. 2020, vol. 1, issue 1, pp. <http://dx.doi.org/10.26739/2181-0990-2020-1-7>**Ашурова Умида Алишеровна**Доктор философских наук,
Республиканского специализированного научно-практического
медицинского центра Акушерства и гинекологии,
Ташкент, Узбекистан**Абдуллаева Лола Мирзатуллаевна**Доктор медицинских наук,
Республиканского специализированного научно-практического
медицинского центра Акушерства и гинекологии,
Ташкент, Узбекистан**Клычев Спартак Ильхомович**Доктор медицинских наук, профессор
Республиканского специализированного научно-практического
медицинского центра Акушерства и гинекологии,
Ташкент, Узбекистан**Ахмедова Азиза Таировна**Ассистент Самаркандского Государственного Медицинского института
Кафедры Акушерства и гинекологии,
факультета последипломного образования,
Самарканд, Узбекистан.**ХИРУРГИЧЕСКИЙ ПОДХОД К ЛЕЧЕНИЮ ЭНДОМЕТРИОИДНЫХ КИСТ ЯИЧНИКОВ У ПАЦИЕНТОК С БЕСПЛОДИЕМ:
«ЗА» И «ПРОТИВ» (ОБЗОР)**

Ashurova Umida Alisherovna

Falsafa fanlari doktori,
Respublika ixtisoslashtirilgan
akusherlik va ginekologiya ilmiy-amaliy tibbiyot markazi,
Toshkent, O'zbekiston

Abdullayeva Lola Mirzatullayevna

Tibbiyot fanlari doktori,
Respublika ixtisoslashtirilgan
akusherlik va ginekologiya ilmiy-amaliy tibbiyot markazi,
Toshkent, O'zbekiston

Klychev Spartak Ilhomovich

Tibbiyot fanlari doktori, professor
Respublika ixtisoslashtirilgan
akusherlik va ginekologiya ilmiy-amaliy tibbiyot markazi,
Toshkent, O'zbekiston

Axmedova Aziza Tairovna

Samarqand davlat tibbiyot instituti assistenti
Akusherlik va ginekologiya kafedrasini,
Diplomdan keyingi ta'lim fakulteti,
Samarqand, O'zbekiston.

BEPUSHT AYOLLARDA TUXUMDON ENDOMETRIOID KISTALARINI JARROXLIK DAVOSINING O'RNI (ADABIYOTLAR TAHLILI)

Despite a fairly detailed study of ovarian neoplasms, the causes of benign tumors and ovarian cysts, and, consequently, the issues of early diagnosis and prevention of the most common ovarian neoplasms remain open [1,5].

According to foreign authors, surface-epithelial tumors account for 88.7% of all ovarian tumors, of which serous - 68.7%, mucinous - 8.5%, endometrioid - 6.5%, etc. [14].

Risk factors for ovarian tumors are: early menarche, late menopause, menstrual dysfunction, high-calorie diets with a high content of saturated fatty acids, genetic predisposition, infertility, especially hormonal, stimulating therapy, chronic inflammatory diseases of the uterus, smoking, etc. [2]., of a very different nature are found at almost any age of women - from childhood to senile age [1]. With the onset of sexual activity, the clinical picture of benign ovarian formations is supplemented by a complaint of infertility, which is caused not only by hormonal disorders in the ovaries, but also by the presence of a volumetric formation that compresses the cortical substance and disrupts follicle maturation [8]. Previous studies have shown that often only the removal of education by laparoscopy leads to the restoration of fertility [2,3].

It is known that endometriosis affects 6 to 10% of women of reproductive age, and among women with infertility occurs in 25-50% of the population [7]. At the same time, in 17-44% of women suffering from endometriosis, endometrioid ovarian cysts (ECY) are detected, which are often combined with tubal infertility [18]. The management of such patients is a complex and urgent, but not solved problem in the world

On the issue of changes in the ovarian reserve after surgical treatment of ECY, the inconsistency of the literature [6] attracts attention. Thus, according to the results of two prospective cohort studies, a progressive decrease in the ovarian reserve after surgical treatment was revealed, whereas data from earlier studies indicate a partial restoration of the reserve characteristics 3 months after the operation [5]. According to studies by P. Santulli et al. (2016), ECJ is not directly associated with a high risk of infertility, while a history of surgical treatment of endometriosis has turned out to be a significant risk factor for its development. It was shown that repeated surgical removal of recurring ECJ can lead to a more pronounced decrease in ovarian reserve compared with the first operation, and with bilateral endometriomas it is associated with the risk of developing exhausted ovary syndrome, often observed immediately after surgery [14].

The goal of surgical treatment of patients with infertility associated with endometriosis is to restore the correct anatomy while maintaining the function of the pelvic organs [17]. Moreover, according to some authors, surgical treatment instead of expectant

tactics also allows you to increase the frequency of spontaneous pregnancy. Surgical treatment of ECJ is the most common method today (82.2%), however, some authors are inclined to believe that removal of the cyst can damage healthy ovarian tissue and thereby reduce ovarian reserve [12].

P. Vercellini et al. (2014) conducted a large-scale meta-analysis of uncontrolled studies, including a series of cases, according to which the pregnancy rate after surgical treatment of endometriosis was 50%. It should be noted that with a combination of infertility associated with endometriosis and pain, surgical treatment is the optimal approach, the use of which allows you to both get rid of pelvic pain and improve fertility rates [12].

In the case of an unsatisfactory ultrasound picture or with rapidly growing ovarian cysts, surgical treatment should be considered mandatory with the aim of obtaining tissue for subsequent histological examination and excluding possible malignancy [1-5].

The question of the possibility in the preoperative period to determine the nature of the ovarian tumor and to solve the question of the volume and type (laparotomy or laparoscopy) of the operation is still controversial [3]. Not all gynecological hospitals have a morphological laboratory for intraoperative rapid diagnosis of a tumor capsule, which allows you to reasonably choose the operative tactics [1-3].

A large number of scientific studies have been devoted to improving methods for diagnosing ovarian tumors. The main development was received by radiation, immunological research methods, diagnostic laparoscopy. Informative are the ultrasound examination of the pelvic organs in the abdominal and transvaginal ways [18,19].

Russian oncologists consider any ovarian formation to be potentially malignant, which implies a wide range of examinations in the preoperative period, histological verification of the diagnosis and, if necessary, radical surgery. The choice of surgical tactics for the treatment of such tumors is affected by age, the reproductive status of women, and the histotype of education. It is this circumstance that causes the problem of the choice of therapeutic tactics when detecting ovarian cysts, especially in patients with infertility [1,4].

The problem of benign ovarian tumors (DOY) is important not only because of their high prevalence, but also in connection with the widespread use of modern minimally invasive surgical treatment by laparoscopy. However, the likelihood of recurrence and malignancy of ovarian formations or contamination of the abdominal cavity when the tumor is removed in the case of an undiagnosed malignant formation is also an urgent problem [10].

DOIA develop in women of any age in 48-64.5% of cases, but more often in the reproductive period. Due to the increase in the structure of diseases in women of reproductive age, the proportion of retention or tumor-like formations of the ovaries (OOI), DOG, as well as polycystic ovary syndrome, chronic anovulation, which significantly affect the reproductive function of patients characterized by infertility, the problem has social significance [9,10].

About 80% of patients with malignant ovarian formations enter a hospital with common stages of the disease, and this leads to low treatment efficiency and high mortality [1,6,7]. Consequently, the question remains not only of identifying or detecting ovarian formation, but also predicting its nature, i.e. to determine before surgery the malignant, borderline or benign this formation to address the issue of the most optimal access (laparoscopy or laparotomy) [8].

Nevertheless, even in carefully examined patients with ECU-specific ultrasound, the malignant process is detected in 0.9% of cases. The presence of ECJ directly leads to structural changes in the ovarian tissue, which can complicate the collection of oocytes due to both the size and location of the cyst, and the accompanying adhesive process [10,14,15]. In this case, of course, prior surgical removal of cysts is required in order to provide access to the follicles.

The advantages of surgical treatment of ECJ include reducing the severity of pain, preventing cyst rupture, providing access to the follicles and taking oocytes for use in ART. Surgical treatment allows to assess the degree of involvement of the fallopian tubes in the local adhesion process [12]. In addition, a histopathological examination allows you to detect signs of malignancy in the tissue of a distant formation. The question of the ideal method of surgical treatment remains debatable and debated: what should be done - completely remove the cyst with excision of the capsule or conduct drainage followed by ablation of the cyst capsule [15].

It is believed that indications for surgical treatment in young patients should be limited in the absence of severe pelvic pain. In this case, it is necessary to explain to the woman the possible risks of a decrease in ovarian function after surgical treatment. For patients of reproductive age with ovarian operations in the anamnesis at the first stage, it is necessary to evaluate the ovarian reserve.

For patients of reproductive age with ovarian operations in the anamnesis at the first stage, it is necessary to evaluate the ovarian reserve. In those cases where the likelihood of spontaneous conception is small, it is necessary to consider the possibility of using ART [13,16]. Some experts argue that endometriomas larger than 3 cm require surgical removal at the stage of preparation for ART, while others, on the contrary, believe that due to a possible reduction in the ovarian reserve during surgery, surgical treatment should be abstained [18].

In a prospective randomized clinical trial, A. Demiroglu et al. (2016) it was shown that surgical removal of ECY before IVF leads to a decrease in the ovarian response in ART cycles. As the results of histological studies of the removed material showed, during the operation, along with the capsule, healthy ovarian tissue was inadvertently excised, which explains the subsequent decrease in ovarian reserve.

Excessive bipolar coagulation also damages healthy ovarian tissue. Results of a report by I. Streuli et al. (2012) suggest that endometrioma

alone does not reduce the ovarian response, which was assessed by AMH. The decrease in ovarian response in patients with ECY is iatrogenic in nature and is the result of surgical removal of the cyst. In accordance with the results of these studies, the latest recommendations suggest abstaining from surgical treatment of ECY until ART is performed.

Thus, after analyzing the literature data, it can be concluded that: endometrioma is one of the main clinical forms of endometriosis, often combined with infertility; ECYs contain high concentrations of biologically active substances (proteolytic enzymes and inflammatory mediators), which contributes to the structural disorganization of the inner part of the ovarian cortex; high is the frequency of the combination of ECY with tubal infertility; in patients with infertility associated with endometriosis, the goal of surgical treatment should be to restore the correct anatomy while maintaining the functions of the pelvic organs; surgical treatment can reduce the severity of pain, prevent cyst rupture and subsequent infection, intraoperatively evaluate the ovarian reserve by counting, allowing to predict the possibility of pregnancy after surgical treatment, to facilitate the collection of eggs for the purpose of using ART, to assess the degree of involvement of the fallopian tubes in the local adhesion process, to detect signs of malignancy in tissue of a distant formation during histopathological examination; the decision to perform surgical intervention should be carefully weighed and made taking into account the possible reduction in ovarian reserve as a result of the operation [11-16].

Debatable and controversial are the information: that the surgical removal of ECYA has a negative effect on the ovarian reserve; changes in the ovarian reserve after surgical treatment of ECJ (along with its decrease after surgical treatment, a partial restoration of characteristics after the operation is also shown); that the presence of ECJ is not directly associated with a high risk of infertility, while surgical treatment of endometriosis is a significant risk factor for the development of infertility; that surgical treatment instead of expectant tactics also allows you to increase the frequency of spontaneous pregnancy; about the need to remove ECY before the planned IVF; that with a combination of infertility associated with endometriosis and pain, surgical treatment is the only correct approach that allows you to get rid of pelvic pain and directly affects fertility rates; about the ideal method of surgical treatment: complete removal with excision of the cyst capsule or drainage and subsequent ablation of the cyst capsule; that in relation to patients, previously operated on for endometriosis, with reduced ovarian reserve, with no pain and cyst growth, ART should be considered as first-line therapy to reduce the time of pregnancy [7-10].

All this makes it necessary to conduct research aimed at improving the choice of therapeutic tactics for the detection of ECJ in patients suffering from infertility [13].

It is necessary to further study the effect of ECJ on physiological processes in the tissues of the ovary, determining the role of ECJ and surgical treatment of cysts in reducing the ovarian reserve and the likelihood of spontaneous pregnancy and further outcomes [15].

Literature:

1. Ashrafi M, Fakhri T, Kiani K, Sadeghi M, Akhoond MR. Impact of the endometrioma on ovarian response and pregnancy rate in vitro fertilization cycles // *Fertil Steril*. 2014 - № 8(1). – P. 29-34.
2. Bezhenar V.F., Yarmolinskaya M.I. Comparison of the effectiveness of various schemes of hormone-modulating therapy after surgical treatment of external genital endometriosis // *Problemy reproduktivnoy meditsiny*. 2015. - № (4). С 89–98. Russian.
3. Brink Laursen J., Schroll J.B., Macklon K.T. et al. Surgery versus conservative management of endometriomas in subfertile women. A systematic review // *Acta Obstet. Gynecol. Scand*. 2017. - Vol. 96. - P. 727–735.
4. Carrillo, L. et al. The Role of Fertility Preservation in Patients with Endometriosis // *Journal of Assisted Reproduction and Genetics*. 2017. - P. 317–323.
5. Dunselman G.A., Vermeulen N., Becker C. et al. ESHRE guideline: management of women with endometriosis // *Hum. Reprod*. 2014. - Vol. 29, N 3. - P. 400–412.

6. Garavaglia, Elisabetta et al. Fertility Preservation in Endometriosis Patients: Anti-Müllerian Hormone Is a Reliable Marker of the Ovarian Follicle Density // *Frontiers in Surgery*. 2017. - № 40. - P. 286 - 293.
7. Goud PT, Goud AP, Joshi N, Puscheck E, Diamond MP, Abu-Soud HM. Dynamics of nitric oxide, altered follicular microenvironment and oocyte quality in women with endometriosis. // *Fertil Steril*. 2014. – Vol.102(1). -P 151-9.
8. Jain G, Khatuja R, Juneja A, Mehta S. Laparoscopy: as a first line diagnostic tool for infertility evaluation // *J Clin Diagn Res*. 2014. – Vol.8(10). - P:01-02.
9. Kwon SK, Kim SK, Yun SC, Kim DY, Chae HD, Kim CH, et al. Decline of serum antimüllerian hormone levels after laparoscopic ovarian cystectomy in endometrioma and other benign cysts: a prospective cohort study // *Fertil Steril*. 2014. – Vol.101(2). – P. 435-41.
10. Muzii L., Tucci C.D., Feliciano M.D. et al. Infertility associated with ovarian endometriomas: surgery or in-vitro fertilization? // *J. In Vitro Fertilization*. 2017. - Vol. 1, N 1. - P. 1–3.
11. Muzii L., Tucci C.D., Feliciano M.D. et al. Management of endometriomas // *Semin. Reprod. Med*. 2017. - Vol. 35. - P. 25–30.
12. Ovarian Endometrioma: What the Patient Needs / Endometriosis Treatment Italian Club // *J. Minim. Invasive Gynecol.* – 2014. – Vol. 21, № 4. – P. 505–516.
13. Ovarian Endometrioma: What the Patient Needs / Endometriosis Treatment Italian Club // *J.Minim. Invasive Gynecol.* – 2014. – Vol. 21, №4. – P. 505–516.