



Sharafova Inobat Akhmedjonovna

Samarkand State Medical University, Republic of Uzbekistan, Samarkand

ЮЗ НЕРВИ МОНОНЕВРОПАТИЯСИДА ЖИСМОНИЙ РЕАБИЛИТАЦИЯНИНГ ЎРНИ

Шарафова Инобат Ахмеджонова

Самарқанд давлат тиббиёт университети, Ўзбекистон Республикаси, Самарқанд ш.

РОЛЬ ФИЗИЧЕСКОЙ РЕАБИЛИТАЦИИ ПРИ МОНОНЕВРОПАТИИ ЛИЦЕВОГО НЕРВА

Шарафова Инобат Ахмеджонова

Самаркандский государственный медицинский университет, Республика Узбекистан, г. Самарканд

e-mail: goyiboysalim@gmail.com, boboshercc@gmail.com

Резюме. Ушбу мақолада юз нервнинг мононевропатияси (ЮНМ) бўлган болаларда мушак-фасциал аппаратга таъсир қилишининг физик усулларида фойдаланиш натижалари баҳоланди. Тадқиқот юз нервнинг мононевропатияси таъхиси қўйилган беморларни ($n = 60$) кенг қамровли текшириш ва даволаш маълумотларини ўз ичига олади. Даволаш усулига қараб, беморлар икки гуруҳга бўлинган: асосий гуруҳ ($n=31$) – кинезиотейплаш ёрдамида мушак-фасциал сегментни моделлаштириш билан биргаликда стандарт терапияни ўзида мужассам этган мураккаб реабилитация тадбирларини олган ЮНМ билан касалланган беморлар; таққослаш гуруҳи ($n=29$) - асосий стандарт терапия олган ЮНМ билан касалланган беморлар. Ўтказилган динамик кузатишлар шуни кўрсатдики, асосий тадқиқот гуруҳида ЮНМнинг клиник ва неврологик белгилари сезиларли даражада деярли соғлом ҳолатга етди, ўз навбатида таққослаш гуруҳида эса патологик жараён биров ўзгарган. Шундай қилиб, мушаклар-фасциал сегментни моделлаштириш орқали физиотерапия ва жисмоний реабилитацияни ўз ичига олган реабилитация терапияси болаларда ЮНМни даволашда тавсия этилади ва шунингдек, қайта тикловчи даволашда самарали ва зарурий чора-тадбир бўлиб хизмат қилади. Унинг самарадорлиги контрактура ривожланишини ва юз мушакларининг чуқур осилишини олдини олиш, ЮН функционал қобилиятини тиклашдан иборат.

Калим сўзлар: юз нерви невропатияси, болалар, прозопарез, реабилитация, фалаж, дори воситалари, касал болалар.

Abstract. This article evaluates the results of using physical methods of influence of the musculofascial segment in children with facial nerve mononeuropathy (FNN). The study included data from a comprehensive examination and treatment of patients ($n=60$) diagnosed with facial mononeuropathy. Depending on the treatment, the patients were divided into two groups: the main group ($n=31$) – patients with FNN, who underwent a complex rehabilitation technique, including standard therapy in combination with modeling of the musculofascial segment using kinesiotaping; comparison group ($n=29$) – patients with FNN who received basic standard therapy. Conducted dynamic observations showed that in the main study group, the clinical and neurological symptoms of FNN significantly improved, almost to the point of recovery, when compared with the comparison group, in which the pathological process changed slightly. Rehabilitation therapy, which includes physical therapy and physical rehabilitation through modeling of the musculofascial segment, is advisable and important in the treatment of FNN in children, and also serves as an effective and necessary intervention in rehabilitation treatment. Its effectiveness lies in preventing the development of contracture, deep sagging of the facial muscles and restoring the functional abilities of the FN.

Keywords: neuropathy of the facial nerve, children, prosoparesis, rehabilitation, paralysis, drugs, sick children.

Introduction. One of the most common diseases among the cranial nerves (CN) is the pathology of the n.facialis, which entails a violation of facial aesthetics in people in the working period of life [5; 7]. About 11.8% of all diagnosed diseases of the peripheral nervous system are lesions of the facial

nerve, accounting for 28% to 33% of hospitalized patients.

The etiological and pathophysiological mechanisms of Bell's palsy in children are not fully understood. The course of FNN in children is significantly influenced by possible complications, such as con-

tracture of facial muscles caused by defects in the peripheral nervous system (PNS). Ultimately, this can lead to an unfavorable outcome due to the possibility of facial disfigurement and cause various psychological disorders of an emotional nature. Rehabilitation of the function of facial muscles due to the presence of neuropathy of the facial nerve entirely depends on the diagnosis and probable complications in the future. Almost complete rehabilitation of the function of facial muscles after suffering neuropathy of the facial nerve is observed in 80% of cases after 4-6 weeks. Every fifth case of rehabilitation can be delayed for a period of six months to a year due to the development of concomitant complications or severe damage to the FN. The existing residual effects and complications associated with FNN require the search for effective methods of recovery and rehabilitation of children, allowing to reduce the frequency of their occurrence, are relevant and require further in-depth study.

Purpose of the study. To evaluate the results of the use of electrical neuromyostimulating and modeling methods of the muscular-fascial segment in children with FNN, depending on the factors of occurrence, duration of the disease and possible complications.

Materials and methods. The study included data from a comprehensive examination and

treatment of patients (n=60) diagnosed with facial neuropathy. Depending on the treatment, the patients were divided into two groups: the main group (n=31) – patients with FNN, who underwent a complex rehabilitation technique, including standard therapy in combination with electrical stimulation and modeling of the musculofascial segment using kinesiotaping; comparison group (n=29) – patients with FNN who received basic standard therapy. The control group (n=32, retrospective material) - practically healthy children who underwent medical examination at the place of residence (Fig. 1).

The severity of the lesion was assessed using the following scales: the 6-point House - Brackmann scale and the Nottingham system for assessing the symmetry of facial movement.

To prevent the occurrence of complications on the affected side in the form of loss of physiological position (sagging) by the facial muscles, a reflex method of modeling the muscular-fascial segment was used - kinesio taping. Kinesio tapes were applied to the occipitofrontalis muscle (m. occipitofrontalis); muscle that lifts the angle of the mouth (m. levator anguli oris); zygomatic minor and major muscles (m. zygomaticus major et minor). When applying tapes, the level and degree of damage to the facial nerve were taken into account.

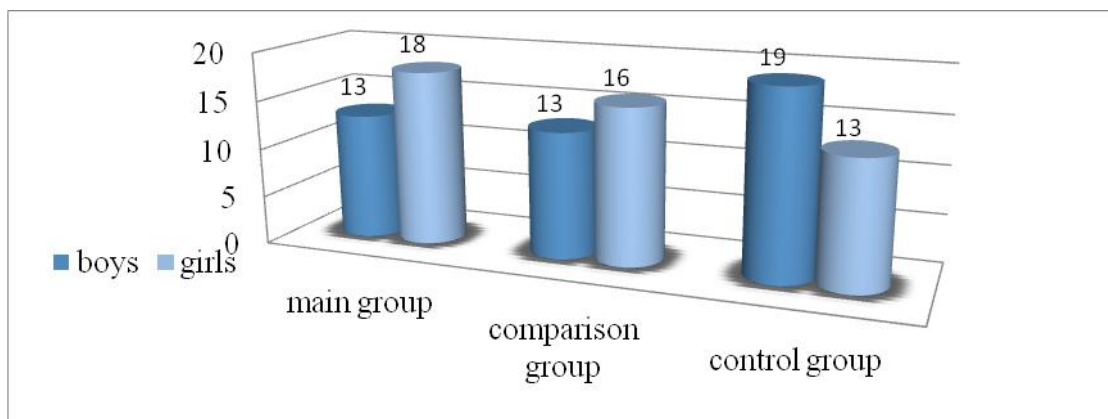


Fig. 1. Distribution of children by study group and gender

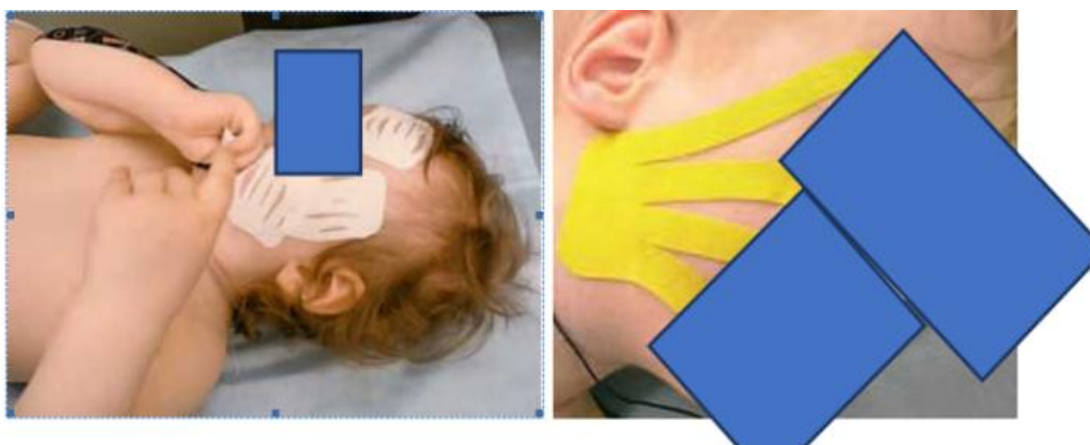

Fig. 2. Technique for applying tape: A) “Basket” type, tension up to 40%; B) For lymphatic drainage, tension 5-15%

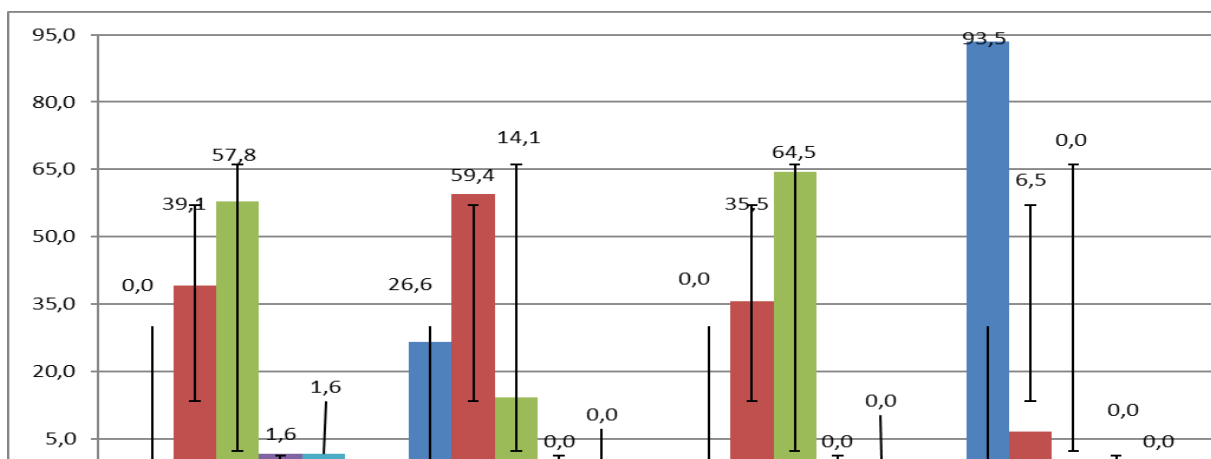


Fig. 3. Qualitative indicators of the degree of prosoparesis according to the House-Brackmann scale over time in the study groups

Research results. The characteristic clinical symptoms of this disease, regardless of the topographic location of the affected area, will be prosoparesis and prosoplegia, manifested by a deficiency of movement in the facial muscles on the affected half of the face. An objective examination reveals smoothness of the palpebral fissure and skin folds, facial asymmetry, drooping of the corner of the mouth, Bell's sign, lagophthalmos, as well as a decrease in corneal and superciliary reflexes [3; 4].

Assessment of the severity of the lesion depending on the degree is carried out using the House - Brackmann scale, the Nottingham system for assessing facial symmetry [1; 2].

The International Kinesio Taping Association (KTAI) introduced the kinesio taping method into medical care protocols in the USA, and later in some European countries for Bell's palsy. According to reviews studied in the literature [5], kinesiotaping can distinguish several effects on the body: mechanical and neuroreflex. Mechanical is to increase and activate the microvasculature. The neuroreflex effect is determined by the activation of proprioceptors and reflex reactions from the central nervous system.

To prevent the occurrence of complications on the affected side in the form of loss of physiological position (sagging) by the facial muscles, a reflex method of modeling the muscular-fascial segment was used - kinesio taping. Kinesio tapes were applied to the occipitofrontalis muscle (m. occipitofrontalis); muscle that lifts the angle of the mouth (m. levator anguli oris); zygomatic minor and major muscles (m. zygomaticus major et minor). When applying tapes, the level and degree of damage to the facial nerve were taken into account (Fig. 2).

Conducted dynamic observations showed that in the main study group, the clinical and neurological symptoms of FNN significantly improved, almost to the point of recovery, when compared with the comparison group, in which the pathological process changed slightly.

The decrease in the degree of damage to the FN according to the House - Brackmann scale in the dynamics of treatment was significantly expressed in the main group, so if during the initial examination the degree of damage varied from 2nd to 3rd, the average values in this group reached 2.61 ± 0.09 , then after treatment the degree of damage was from 1st to 2nd, more than 1st degree, averaging 1.61 ± 0.05 [8; 6].

According to the severity of prosoparesis according to the House - Brackmann scale, it was found that in patients of the main group before treatment, moderate dysfunction of the FN predominated - 64.5%, and in 35.5% of cases mild dysfunction was noted (Fig. 3).

Whereas in the comparison group, 57.8% were diagnosed with moderate, 39.1% with mild, and 3.2% with moderate and severe dysfunction of the FN. After treatment, upon re-examination, normal function of all branches of the FN was recorded in 93.5% of patients in the main group, and in the comparison group - in 26.6%, which was significantly significant ($p < 0.01$).

Discussion. According to the obtained anamnestic and questionnaire data, in the study group of patients with neuropathy of the facial nerve, the main etiological factor contributing to the development of the disease was any focus of infection causing inflammation, and therefore the history most often revealed repeated cases of acute respiratory viral infections, pathologies of the ENT organs and dental caries.

Considering the anatomical location of the FN and its blood supply, the spread of the inflammatory process occurs quite quickly, especially in children. In patients with FNN, during the period of active inflammation, as well as recovery, instability of the immune system is determined, associated both with FN damage and the presence of inflammatory processes of an infectious-bacterial nature, which are reflected in the levels of changes in the concentrations of inflammatory markers.

Severe disorders in FNN are associated with a breakdown of the adaptation and mobilization mechanisms of the immune response, especially in the recovery period, which indicates the presence of chronic inflammatory processes in the body of children (dental caries, pathology of the ENT organs, frequent acute respiratory viral infections). This dictates the need to study the characteristics of the immune system (IS), as well as inflammatory markers that have a certain relationship in the occurrence of facial nerve neuropathy and the impact on the severity of its clinical manifestations.

Facial nerve neuropathy is a disease characterized by degenerative changes in the facial nerve, causing paresis or paralysis of the facial muscles, with subsequent possible severe functional, aesthetic and psychological disorders. At the same time, a serious danger is determined by the complexity and duration of the recovery period of the functional activity of facial muscles, which is the main cause of disability and social maladjustment of this contingent of patients.

According to the literature, among all existing pathologies of the PNS, FNN accounts for only 3% - 35-50 cases per 10,000 population, is characterized by the absence of gender differences, but the incidence rate may change throughout life.

The FN plays a critical role in numerous complex functions in human life, such as chewing, speech, and social communication through the expression of moods and emotions.

FNN is highly distressing and can be debilitating for those affected, causing functional impairment and aesthetic impairment. Functional deficiency is expressed in a number of clinical manifestations, such as: facial asymmetry, weakness of the lower half of the face, drooping corner of the mouth, spontaneous drooling at rest, leakage of liquid or liquid food when ingested, decreased chewing force and weakness when chewing, asymmetrical smile and dysarthria (slurred speech or decreased clarity of speech). Also, according to the literature, in addition to functional disorders, FNN has a negative impact on the quality of life (QOL) and the emotional state of patients, significantly reducing it, sometimes even to the point of neurodepressive disorders.

When assessing the objective status, the main clinical symptoms are: Bell's symptom, lagophthalmos, decreased corneal and superciliary reflexes, narrowing of the palpebral fissure and smoothness of the nasolabial fold, facial asymmetry.

The severity of the lesion is currently recommended to be assessed using the House-Brackmann scale and the Nottingham grading system.

The basis of FN damage is a multifactorial, polyetiological process. Until now, there is no consensus on the mechanisms of development of FNN in children; it is known that in adults its occurrence is

associated with circulatory disorders, while in children it may be associated with the development of autoimmune processes. The outcome of the disease, the presence of complications and relapses of FNN in children are determined by inflammatory factors, as well as the anatomical features of the structure of the skull, which has a narrow bone canal through which the FNN passes.

From a pathogenetic point of view, the occurrence of FNN can be explained by the lymphogenous theory. Complicated processes of FNN in children in the form of contractures and synkinesis of facial muscles are rarely observed. Relapses may be associated with age-related hormonal changes in the body during adolescence.

There are central and peripheral lesions of the facial nerve. Central paralysis of the FN is the result of damage to its central segment (facial nucleus or connections between them), which clinically manifests itself as a unilateral movement disorder opposite the side of the lesion, with a predominance in the lower part of the face. Central paralysis can be caused by the following pathologies: multiple sclerosis, cerebral infarction, hematomas due to arterial hypertension, brain contusions, tumor processes, etc.

Peripheral paralysis of the FN occurs as a result of trauma or bruises of the brain, face, may be generic, also caused by tumors, various neurological syndromes (Guillain-Barré, etc.), inflammatory neuritis, metabolic disorders, postoperative complications (during operations on the mastoid process, parotid glands, middle ear), idiopathic.

The standard method for diagnosing FNN is ENMG; it allows recording muscle activity, determining the topic of the damaged FN, the nature of the course of the disease, its severity, the possibility of carrying out treatment and rehabilitation measures, and prognosis of the safety of nerve fibers.

The diagnostic method for FNN is considered to be neuroimaging of the FN - neurosonography (NSG of the facial nerve). This method makes it possible to predict the remyelination of FN fibers and to visualize the extracranial part of the cranial nerves in real time using high-resolution sensors.

Based on the above, insufficient attention is paid to the diagnosis of FNN, especially in childhood; there are fewer studies than in adult practice, although statistical data on mononeuropathies are very disappointing and indicate the need for an in-depth study of the actual problem and the solution of a number of issues, including evaluation of effectiveness existing methods of treatment and development of optimal rehabilitation programs for FNN in children.

Conclusions. Rehabilitation therapy, which includes physical therapy and physical rehabilitation through modeling of the musculofascial segment, is advisable and important in the treatment of FNN in

children, and also serves as an effective and necessary intervention in rehabilitation treatment. Its effectiveness lies in preventing the development of contracture, deep sagging of the facial muscles and restoring the functional abilities of the FN. A rehabilitation complex, prescribed individually taking into account clinical symptoms and diagnostic indicators, allows for faster elimination of both clinical symptoms and provides long-term pathophysiological regression, having a beneficial effect on vascular, muscle, nervous and connective tissues, which in turn reduces the duration of hospitalization.

Literature:

1. Anvarbekova Y.A., Alymkulov R.D. Rehabilitation of patients with facial nerve neuropathies using traditional Kyrgyz and Chinese medicine // Bulletin of the KSMA named after. I.K. Akhunbaeva. - 2019. - No. 1. - P. 44-48
2. Andreeva G. O. New technique of acupuncture in the treatment of neuropathy of the facial nerve // Bulletin of St. Petersburg University. - 2010. - No. 4. - P. 36-41
3. Miftakhov A.F. Therapeutic physical culture for neuritis of the facial nerve / A.F. Miftakhov // NovaInfo.Ru. – 2020. – No. 112. – P. 60-62
4. Savitskaya N.G., Yankevich D.S., Ostafiychuk A.V., Pavlov E.V. Electromyography: prognosis and assessment of the effectiveness of therapy for Bell's palsy // Neurology, neuropsychiatry, psychosomatics. - 2011. - No. 3. - P. 60-64
5. Eidlitz-Markus T., Gilai A, Mimouni M. et al. Recurrent facial nerve palsy in paediatric patients // Eur j Pediatr. 2001. - V. 160. - P. 659-663
6. Sharafova IA et al. Kinesiotaping: New Look at the Rehabilitation of Facial Nerve Neuropathy in Children // Annals of the Romanian Society for Cell Biology. – 2021. – pp. 4763-4768.
7. Baratova S.S., Mavlyanova Z.F., Sharafova I.A. Individual typological features that determine the choice of type of sports activity //Modern problems of psychology and education in the context of working with various categories of children and youth. – 2016. – P. 190-191.
8. Sharafova I. A., Burkhanova G. L. BASIC APPROACHES TO COMPLEX TREATMENT OF FACIAL NERVE NEUROPATHY IN CHILDREN // Bulletin of Science and Education. – 2020. – No. 25-2 (103).
9. Sharafova IA BASIC APPROACHES TO THE COMPLEX TREATMENT OF FACIAL NEUROPATHY IN CHILDREN //Journal of Modern Educational Achievements. – 2023. – Т. 8. – No. 8. – pp. 47-53.
10. Sharafova I. A. et al. Etiopathogenetic aspects of the clinical course of prosoparesis in children //

Science and Education. – 2023. – Т. 4. – No. 6. – pp. 332-338.

11. Sharafova I. A. et al. Correlation dependence of neuroimaging and electrofunctional indicators in peripheral lesions of the facial nerve in children // Science and Education. – 2023. – Т. 4. – No. 6. – pp. 316-323.

12. Sharafova IA NEUROIMAGING AS A MODERN METHOD OF DIAGNOSTICS AND PROGNOSIS OF REHABILITATION IN CHILDREN WITH FACIAL NERVE LESIONS //Journal of Modern Educational Achievements. – 2023. – Т. 8. – No. 8. – pp. 42-46.

13. Sharafova IA et al. Kinesiotaping: New Look at the Rehabilitation of Facial Nerve Neuropathy in Children // Annals of the Romanian Society for Cell Biology. – 2021. – pp. 4763-4768.

14. Sharafova I. A., Kim O. A. An integrated approach to the treatment and rehabilitation of patients with neuropathy of the facial nerve // Youth and medical science in the XXI century. – 2019. – P. 210-210.

РОЛЬ ФИЗИЧЕСКОЙ РЕАБИЛИТАЦИИ ПРИ МОНОНЕВРОПАТИИ ЛИЦЕВОГО НЕРВА

Шарафова И.А.

Резюме. В данной статье оценены результаты применения физических методов воздействия на мышечно-фасциальный аппарат у детей с мононевропатией лицевого нерва (НЛН). В исследование включены данные комплексного обследования и лечения больных (n=60) с диагнозом мононевропатия лицевого нерва. В зависимости от проводимого лечения пациенты были разделены на две группы: основная группа (n=31) – пациенты с НЛН, которым проводилась комплексная методика реабилитации, включающая стандартную терапию в сочетании с моделированием мышечно-фасциального сегмента методом кинезиотейпирования; группа сравнения (n=29) – пациенты с НЛН, получавшие базисную стандартную терапию. Проведенные динамические наблюдения показали, что в основной группе исследования клинично-неврологическая симптоматика НЛН значимо улучшалась, практически до выздоровления при сопоставлении с группой сравнения, в которой патологический процесс изменялся незначительно. Таким образом, реабилитационная терапия, которая включает физиотерапию и физическую реабилитацию посредством моделирования мышечно-фасциального сегмента, целесообразна и имеет важное значение при НЛН у детей, а также служит эффективным и необходимым мероприятием при восстановительном лечении. Её эффективность заключается в предупреждении развития контрактуры, глубокого обвисания мимических мышц и восстановлении функциональных способностей ЛН.

Ключевые слова: невропатия лицевого нерва, дети, прозопарез, реабилитация, паралич, лекарственные средства, больные дети.