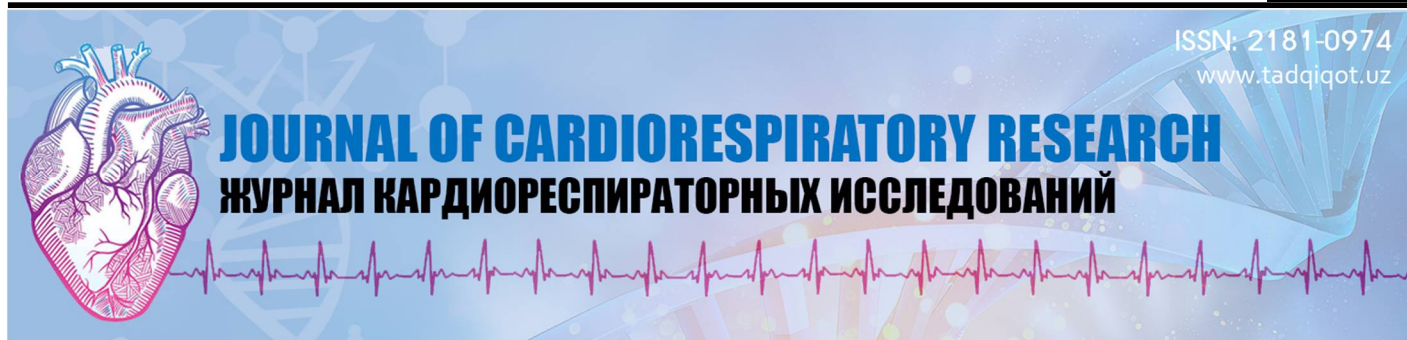



**Гайбуллаев Жавлон Шавкатович**


ассистент кафедры педиатрии №1 и неонатологии,  
Самаркандский государственный  
медицинский университет  
Самарканд, Узбекистан

**Алланазаров Алишер Боймуратович**

Самаркандский Государственный  
медицинский университет  
Самарканд, Узбекистан

### ОСТРЫЙ МИОКАРДИТЫ У ДЕТЕЙ НА ФОНЕ БРОНХО-ЛЕГОЧНЫХ ИНФЕКЦИЙ

**For citation:** Gaybullaev J.Sh., Allanazarov A.B. ACUTE MYOCARDITIS IN CHILDREN ON THE BACKGROUND OF BRONCHO-PULMONARY DISEASES. Journal of cardiorespiratory research. 2023, vol 4, issue 1, pp.46-48

 <http://dx.doi.org/10.5281/zenodo.7919984>

#### АННОТАЦИЯ

Бронхо-легочные заболевания у детей - одна из актуальных проблем педиатрии, что определяется сохраняющейся высокой заболеваемостью и тяжелым прогнозом, особенно у детей раннего возраста. Целью исследования явилась определить клиническую характеристику острого миокардита у детей на фоне бронхо-легочных заболеваний. Было обследовано 64 детей в возрасте от 6 месяцев до 7 лет с пневмонией, которых мы разделили на 2 группы. В I группу (контрольную) включили 32 детей, которые были только с респираторными жалобами. Во II группу (основную) вошло 32 больных детей с пневмонией, имевшие нарушение со стороны сердечно-сосудистой системы, наличие которых было подтверждено инструментальными методами. Полученные результаты подчеркивают, что на фоне бронхо-легочной патологии пневмония маскируется все симптомы острой сердечной недостаточности, причиной которого в большинстве случаев является острая коронарная недостаточность, изменение сердечной мышцы при этой патологии у детей повышает риск возникновения тяжелых нежелательных осложнений со стороны сердца.

**Ключевые слова:** острый миокардит, бронхо-легочные заболевания, дети.

**Gaybullaev Javlon Shavkatovich**

assistant of the Department of 1 Pediatrics and Neonatology  
Samarkand State Medical University,  
Samarkand, Uzbekistan

**Allanazarov Alisher Boymuratovich**

assistant of the Department of 1 Pediatrics and Neonatology  
Samarkand State Medical University,  
Samarkand, Uzbekistan

### ACUTE MYOCARDITIS IN CHILDREN ON THE BACKGROUND OF BRONCHO-PULMONARY DISEASES

#### ANNOTATION

Broncho-pulmonary diseases in children is one of the urgent problems in pediatrics, which is determined by the continuing high incidence and severe prognosis, especially in young children. The aim of the study was to determine the clinical characteristics of acute myocarditis in children with acute broncho-pulmonary diseases. We examined 64 children aged 6 months to 7 years with broncho-pulmonary diseases, which we divided into 2 groups. Group I (control) included 32 children who had only respiratory complaints. Group II (main) included 32 sick children with broncho-pulmonary diseases, who had a violation of the cardiovascular system, the presence of which was confirmed by instrumental methods. The results obtained emphasize that against the background of broncho-pulmonary diseases, all symptoms of acute heart failure are masked, the cause of which in most cases is acute coronary insufficiency; changes in the heart muscle in this pathology in children increases the risk of severe unwanted heart complications.

**Keywords:** acute myocarditis, broncho-pulmonary diseases, children.

**G'aybullaev Javlon Shavkatovich**

1-pediatriya kafedrası assistenti,  
Samarqand davlat tibbiyot universiteti  
Samarqand, O'zbekiston

Allanazarov Alisher Boymuratovich  
1-pediatriya kafedrası assistenti,  
Samarqand davlat tibbiyot universiteti  
Samarqand, O'zbekiston

## BOLALARDA BRONX-O'PKA KASALLIKLARI FONIDAGI O'TKIR MIOKARDITLAR

ANNOTATSIYA

Bolalardagi bronx-o'pka kasalliklari pediatriyaning dolzarb muammolaridan biri bo'lib, bu, ayniqsa yosh bolalarda davom etayotgan yuqori insidans va og'ir prognoz bilan belgilanadi. Tadqiqotning maqsadi bronx-o'pka kasalliklari fonida bolalarda o'tkir miokarditning klinik xususiyatlarini aniqlash edi. Biz pnevmoniya bilan og'rigan 6 oylikdan 7 yoshgacha bo'lgan 64 nafar bolani tekshirdik, ularni 2 guruhga ajratdik. Guruh I (nazorat) faqat nafas olish shikoyatlari bo'lgan 32 bolani o'z ichiga oldi. II guruhga (asosiy) yurak-qon tomir tizimining buzilishi bo'lgan pnevmoniya bilan og'rigan 32 nafar bemor bolalar kiradi, ularning mavjudligi instrumental usullar bilan tasdiqlangan. Olingan natijalar shuni ko'rsatadiki, pnevmoniyaning bronx-o'pka patologiyasi fonida o'tkir yurak etishmovchiligining barcha belgilari niqoblanadi, uning sababi ko'p hollarda o'tkir koronar etishmovchilik bo'lib, bolalarda ushbu patologiyada yurak mushaklaridagi o'zgarishlar xavfni oshiradi va jiddiy salbiy yurak asoratlariga olib keladi.

**Kalit so'zlar:** o'tkir miokardit, bronx-o'pka kasalliklari, bolalar

**Relevance.** For several decades, severe broncho-pulmonary diseases have remained one of the urgent problems of modern medicine due to the steady trend towards an increase in the number of patients and a consistently high mortality rate, despite the use of new principles and methods of treatment [3, 4]. The probable reason for this is the delayed diagnosis and, as a consequence, late initiation of treatment, as well as the impossibility of conducting an adequate assessment of the effectiveness of therapy. The diagnosis of broncho-pulmonary diseases in children is often difficult, especially if signs of respiratory failure have developed against the background of ARVI. The problem of acute myocarditis is currently due to its widespread occurrence, especially in childhood.

One of the main causes of acute myocarditis today is acute respiratory viral infections (ARVI), which remain the most common and global diseases in children. Cardiovascular failure is common in broncho-pulmonary diseases, especially in young children. It develops rapidly, already in the early stages of the disease. With an uncomplicated course of the disease, clinically latent heart failure occurs, it is diagnosed with the help of instrumental studies such as ECG, Echo CG. With broncho-pulmonary diseases in children, dysfunction of the cardiovascular system can clinically manifest itself in the form of coronary insufficiency, and more often cardiovascular failure. [2, 7, 9,]. Each flu epidemic accompanied with a complication of broncho-pulmonary diseases in children is associated with an increase in the number of cases of acute myocarditis, which determines the urgency of studying this problem.

An even more serious task is the timely diagnosis of complications of broncho-pulmonary diseases, especially myocarditis since the identification of this cardiac complication allows you to avoid severe and sometimes fatal consequences for the patient. Previously developed clinical criteria, diagnostic criteria for the diagnosis of heart failure are not always objective enough to identify circulatory disorders in young children. For example, anxiety, decreased appetite, poor sleep-in children are almost always noted. Tachypnea and tachycardia can be not only a sign of broncho-pulmonary diseases, but also occur in a healthy child during examination, feeding, etc. Shortness of breath, tachypnea is always accompanied by diseases of the bronchi and lungs. The frequency of myocarditis in Broncho-pulmonary diseases according to different authors varies from 1 to 15%. From a diagnostic point of view, there are no specific electrocardiographic changes characteristic only for myocarditis.

Myocarditis is an inflammatory lesion of the heart muscle of an infectious, toxic-infectious, infectious-allergic, autoimmune, and toxic etiology [6]. This disease is predominantly of children and young people, although the disease can develop at any age. Any viral or bacterial agents, as well as non-infectious factors, can be the cause of myocarditis. The most common cause of the disease is viruses. In 6-8% of cases, myocarditis develops during or shortly after various sporadic or epidemic viral infections [1].

Of the bacterial myocarditis, the most dangerous are diphtheria (infectious toxic), myocarditis with scarlet fever, typhoid fever and salmonellosis, tuberculosis, yersiniosis (intestinal and

pseudotuberculosis), with generalized streptococcal and staphylococcal infections, 10 pathogens associated with these [8, 14-18]

**Purpose.** To determine the clinical characteristics of acute myocarditis in children with broncho-pulmonary diseases.

**Materials and research methods.** We examined children aged 6 months to 7 years with broncho-pulmonary diseases, who were hospitalized in the emergency pediatrics and children's intensive care units of the SB of RSCEMA. The average age of the examined children was 2.7 years old. The exclusion criteria were a previous infectious disease within a month before hospitalization, the presence of organic heart disease (congenital and acquired heart defects, cardiomyopathy), the presence of signs of rheumatic fever and coronary artery disease. A total of 64 patients with broncho-pulmonary diseases who met the exclusion criteria were included in the study.

The patients were randomly divided into 2 groups Group I (control) included 32 children who had only respiratory complaints. Group II (main) included 32 sick children with broncho-pulmonary diseases, who had a violation of the cardiovascular system.

Evaluation of the effectiveness of the therapy for broncho-pulmonary diseases according to the standard was carried out based on objective signs of cyanosis, congestive wheezing in the lungs and tachycardia. Assessment of the severity of cyanosis in patients was assessed by central and peripheral distribution, and cough by a 4-point system: 0 points - no cough, 1 point - a single cough, 2 points - moderately expressed cough and 3 points - frequent, painful cough. Tachycardia and cyanosis were the main signs of heart damage in Broncho-pulmonary diseases, which tended to continue even against the background of the disappearance of intoxication from the underlying disease.

Additional criteria for the effectiveness of therapy were the duration of oxygen therapy and the duration of hospitalization. Patient management was carried out in accordance with the specifics of the Emergency Medical Service, diagnostic and treatment standards (the recommended deadlines for inpatient treatment of bronchopulmonary diseases were observed). Discharge criteria were satisfactory condition, SpO<sub>2</sub> ≥95%, reduction in cough, shortness of breath and tachycardia. The presence of changes in the electrocardiographic study of "metabolic nature" according to the conclusion of the cardiologist and insignificant preserved oral cyanosis were not a contraindication for discharge. The observation of the patients continued until the main symptoms of the disease were completely resolved.

**Research results and discussion.** After the study, the main indicators of patients in the compared groups were analyzed and compared at admission to the hospital. The analysis showed that the patients selected for the main and control groups were comparable in terms of gender, age, target indicators. Upon repeated examination of children with cardiac disorders at discharge, the following hemodynamic parameters remained: LVEF in the treatment group decreased 45.6 ± 9.6% to 26 ± 6.7% to in the placebo group, where there was a decrease in EF from 27.7 ± 5.6% to 21.3 ± 5.3%; of course, the diastolic volume in the treatment group decreased from 25.7 ± 50.1 to 140.7 ± 50.6 vs in the placebo group, where EDV increased from 245 ± 46.3 to 280.6 ± 48.9. The most frequent changes recorded on the ECG

are sinus tachycardia, which was noted in 18(39.1%) patients, ST segment changes in 12, AV block in 4(8,7%), left bundle branch block in 22(47,8%) patients. Thus, the most valuable electrocardiographic parameter in patients with myocarditis, is a change in the QRS complex.

The results of our study show that it is necessary to conduct echo cardiographic, as well as electrocardiographic studies of children with broncho-pulmonary diseases, causes a decrease in complicated cardiorespiratory syndromes and post hypoxic changes in the ventricular myocardium, which allows us to conclude that there is a certain advantage of preventive examination to prevent the development of chronic cardiovascular pathology. The most frequent changes recorded on the ECG were sinus tachycardia, which was noted in 18 (39.1%) patients, ST segment changes in 12, AV block in 4 (8.7%), left bundle branch block in 22 (47, 8%) patients.

Studies have shown that at present, the criteria for early detection of cardiac pathology in patients with broncho-pulmonary diseases have not been sufficiently developed. Due to the fact that the number of cardiac pathologies at autopsy significantly exceeds its lifetime detection, the problem of early diagnosis of cardiovascular pathology and risk factors for its development in sick children with broncho-pulmonary diseases remains an urgent issue of clinical medicine [4].

Among the pulmonary and extrapulmonary complications of broncho-pulmonary diseases, an important place is occupied by lesions of the cardiovascular system [2,4]. According to many authors [1,10], dysfunction of the cardiovascular system is an almost constant companion of broncho-pulmonary diseases and develops from the first hours; at the same time, circulatory disorders often determine the prognosis and outcome of broncho-pulmonary diseases itself.

**Conclusion.** Thus, the clinical manifestations of heart failure in early childhood are non-specific, which to clarify the diagnosis, it is necessary to conduct a complete clinical and instrumental study, including an ECG with the calculation of indicators of central hemodynamics. An echocardiographic study of children with broncho-pulmonary diseases leads to a decrease in complicated cardiorespiratory syndromes and post-hypocal changes in the ventricular myocardium, which allows us to conclude that there is a certain advantage of preventive examination to prevent the development of chronic cardiovascular pathology under the "mask" of broncho-pulmonary diseases in children and further transformation of the disease into various cardiopathy.

### Список литературы / References / Iqriboslar

1. Afonaskov O.V. Acute myocarditis in young patients with broncho-pulmonary diseases / Dis. Cand. honey. Sciences. - Khabarovsk, 2005. - 127 p.
2. Bakirova V.E. Assessment of the variability of respiratory and heart rhythms in patients with Broncho-pulmonary diseases7 Dis. .kand. honey. nauk.-Ufa, 2006.-159 p.
3. Basargina, E.N. Myocarditis in children: a guide for doctors / E.N. Basargin. - M., 2008.-- 27 p.
4. Board LB, Chernik M.B. Factors affecting the course of broncho-pulmonary diseases // Abstracts of the 13th National Congress on Respiratory Diseases. November 10-14, 2003 St. Petersburg., 2003.-- S. 236.
5. Vishnyakova L.A., Nikitina M.A., Petrova S.I. et al. The role of Streptococcus broncho-pulmonary disease, Mycoplasma broncho-pulmonary diseases and Chlamydia broncho-pulmonary diseases in Broncho-pulmonary diseases in children // Pulmonology. - 2008. - No. 3. - S. 43-47.
6. Grigoriev K.I. Modern view of broncho-pulmonary diseases in children and approaches to its treatment and prevention // Medical assistance. - 2005. - No. 2. - S. 3-9.
7. Clinical guidelines for pediatric cardiology and rheumatology / ed. M.A. Shkolnikova, E.I. Alekseeva. - M., 2011. 143 p.
8. Leontieva I.V. Lectures on pediatric cardiology. Medical practice. 2005.318-322
9. Ruzhentsova, T.A. Metabolic therapy of myocarditis and cardiomyopathy in children with common acute infectious diseases / T.A. Ruzhentsova, A.V. Gorelov, T.V. Smirnova, L.A. Happy // Infectious Diseases. - 2010. - T. 8, No. 3. - P.39-45.
10. Strelyaeva, A.V. Toxic cardiopathy and myocarditis of pecilomycosis and other etiology in children / A.V. Strelyaeva, H.N. Shadyeva, N.B. Lazareva [et al.] // Russian journal of cardiology. - 2010. - No. 3. - P.46-52.
11. Насирова А. А. ХАРАКТЕРИСТИКИ КАЧЕСТВА ЖИЗНИ БОЛЬНЫХ БРОНХИАЛЬНОЙ АСТМОЙ, ХРОНИЧЕСКОЙ ОБСТРУКТИВНОЙ БОЛЕЗНЮ ЛЕГКИХ И ИХ СОЧЕТАНИЕМ //Журнал кардиореспираторных исследований. – 2022. – Т. 3. – №. 3. Насирова А. А., Бабамурадова З. Б., Базарова С. А. Особенности иммунологических показателей у больных хронической обструктивной болезнью легких и бронхиальной астмой //Журнал кардиореспираторных исследований. – 2020. – Т. 1. – №. 3.
12. Насирова А. А., Садикова Ш. Н., Курбанова З. П. Современные представления о роли поверхностного фенотипа лимфоцитов при хронической обструктивной болезни легких и бронхиальной астме и их лечение //Вестник науки и образования. – 2020. – №. 13-2 (91). – С. 49-53.
13. Насирова А. А., Садикова Ш. Н., Курбанова З. П. Современные представления о роли поверхностного фенотипа лимфоцитов при хронической обструктивной болезни легких и бронхиальной астме и их лечение //Вестник науки и образования. – 2020. – №. 13-2 (91). – С. 49-53.
14. Мирзаев, Р. З., Ташкенбаева, Э. Н., & Абдиева, Г. А. (2022). ПРОГНОСТИЧЕСКИЕ КЛИНИЧЕСКИЕ МАРКЕРЫ ПОЧЕЧНОЙ НЕДОСТАТОЧНОСТИ ПРИ МЕТАБОЛИЧЕСКОМ СИНДРОМЕ. Журнал кардиореспираторных исследований, (SI-2).
15. Ризаев Ж. А. и др. Анализ активных механизмов модуляции кровотока микроциркуляторного русла у больных с пародонтитами на фоне ишемической болезни сердца, осложненной хронической сердечной недостаточностью //Вісник проблем біології і медицини. – 2019. – №. 4 (1). – С. 338-342.
16. Ташкенбаева, Э., Абдиева, Г., Хайдарова, Д., & Саидов, М. (2021). Распространенность метаболического синдрома у пациентов с ишемической болезнью сердца. Журнал кардиореспираторных исследований, 2(1), 85-88.
17. Зиядуллаев Ш. Х. и др. Роль некоторых регуляторных цитокинов в иммунопатогенезе экзогенных аллергических альвеолитов //Здобутки клінічної і експериментальної медицини. – 2017. – №. 1. – С. 38-41.
18. Fattaeva D. R., Rizaev J. A., Rakhimova D. A. Efficiency of Different Modes of Therapy for Higher Sinus after COVID-19 in Chronic Obstructive Pulmonary Disease //Annals of the Romanian Society for Cell Biology. – 2021. – С. 6378–6383-6378–6383.