

## STRUCTURAL REMODULATION AND MORPHOMETRIC ANALYSIS OF TRACHEAL WALL ELEMENTS IN ITS ASEPTIC INFLAMMATION



Samieva Gulnoza Utkurovna, Sobirova Shakhlo Bakhtiyorovna, Bakhranova Malika Shavkatovna  
Samarkand State Medical University, Republic Of Uzbekistan, Samarkand

### АСЕПТИК ЯЛЛИГЛАНИШДА ТРАХЕЯ ДЕВОРИ ЭЛЕМЕНТЛАРИНИНГ СТРУКТУРАВИЙ РЕМОДУЛЯЦИЯСИ ВА МОРФОМЕТРИК ТАҲЛИЛИ

Самиева Гулноза Уткуровна, Собирова Шахло Бахтиёровна, Бахранова Малика Шавкатовна  
Самарканд давлат тиббиёт университети, Ўзбекистон Республикаси, Самарканд ш.

### СТРУКТУРНАЯ РЕМОДУЛЯЦИЯ И МОРФОМЕТРИЧЕСКИЙ АНАЛИЗ ЭЛЕМЕНТОВ СТЕНКИ ТРАХЕИ ПРИ ЕЕ АСЕПТИЧЕСКОМ ВОСПАЛЕНИИ

Самиева Гулноза Уткуровна, Собирова Шахло Бахтиёровна, Бахранова Малика Шавкатовна  
Самаркандский государственный медицинский университет, Республика Узбекистан, г. Самарканд

e-mail: [samg83@rambler.ru](mailto:samg83@rambler.ru), [shahlohon.sabirova@gmail.com](mailto:shahlohon.sabirova@gmail.com), [bakhranovam.0603@mail.ru](mailto:bakhranovam.0603@mail.ru)

**Резюме.** Нафас олиш йўллари шиллиқ қаватининг яллигланиши организмнинг ҳужайра, тўқима ва иммунитет даражаларида патоморфологик жараён билан бирга келади. Яллигланиш жараёнини ўрганишга қаратилган тадқиқотларда тўқималарнинг шикастланиши патогенези масалаларини ишлаб чиқиш, юзага келиши мумкин бўлган асоратларни башорат қилиш ва уларни олдини олиш тамойиллари ва усулларини ишлаб чиқиш энг долзарб ҳисобланади. Яллигланиш реакцияларини амалга оширадиган асосий тизим қон тизими бўлиб, унинг зарарли восита таъсирига жавоби ҳисобланади. Бу ҳимоя функциялари билан фаол лейкоцитларни ишлаб чиқаришни кўпайтириш орқали тананинг муҳофафасини рағбатлантириш орқали яллигланишнинг олдини олиш ва доволашнинг мақсадга мувофиқлигини аниқлайди.

**Калит сўзлар:** асептик яллигланиш, структуравий ремодуляция, эпидермоид дифференциация.

**Abstract.** Inflammation of the mucous membrane of the respiratory tract is accompanied by a pathomorphological process at the cellular, tissue and immune levels of the body. In studies aimed at studying the inflammatory process, the most relevant is the development of issues of the pathogenesis of tissue damage, forecasting possible complications and developing principles and methods for preventing them. The main system implementing inflammatory reactions is the blood system, its response to the action of a damaging agent. This determines the feasibility of preventing and treating inflammation by stimulating the body's defenses through increased production of active leukocytes with protective functions.

**Key words:** aseptic inflammation, structural remodulation, epidermoid differentiation.

**Introduction.** Inflammation of the mucous membrane of the respiratory tract is accompanied by a pathomorphological process at the cellular, tissue and immune levels of the body. In studies aimed at studying the inflammatory process, the most relevant is the development of issues of the pathogenesis of tissue damage, prediction of possible complications and development of principles and methods for their prevention.

In modern medicine, the assessment of the role of acute inflammation in human organs in protective and adaptive processes is still relevant. The mechanisms and factors that ensure the chronicity of inflammation and the loss of its protective and adaptive significance have not been sufficiently studied. An important role in the occurrence and maintenance of the inflammatory process in the bronchial tree is given to various cellular and molecular factors [4, 8, 12]. According to C. Boxall, S.T. Holgate

(2012), TGF- $\beta$ 1 has a pronounced local immunoregulatory, regenerative effect. Under the influence of cold air, protective and adaptive processes in the respiratory organs at the cellular and subcellular level are launched in humans. The effect of low temperatures leads to the activation of free-radical processes with an increase in lipid peroxidation reactions, destruction of the membrane apparatus of cells, and inhibition of regenerative processes. Treatment of patients with inflammatory diseases of the respiratory tract is a multi-stage, often lengthy process that requires significant labor and material costs, the use of specialized equipment. The practical significance of the study results is explained by the possibility of using the findings and recommendations when applying diagnostic and therapeutic measures to patients with inflammation of the respiratory tract in medical institutions of various levels, creating the possibility of developing new drugs aimed at treating in-

flammatory diseases of the respiratory organs of the upper respiratory tract and experimentally assessing their effectiveness in an improved experimental model of aseptic inflammation, the ability to study the sequence of changes in the dynamics of tissue structures of the respiratory tract, disruption of the protective properties of various areas of its mucous membrane and the role of inflammatory cytokines by this method. When studying the processes of differentiation in the cells of the epithelial layer of the respiratory tract of adult white rats, we can observe the transition of basal cells into transitional cells, and at the next stages of differentiation, the transition to ciliated, goblet and "brush" cells. Mature ciliated cells do not divide. Since the processes in the small-caliber bronchial epithelium are highly functionally specialized, there is a percentage of cells with high functional specialization that support physiological regeneration processes in them [2,3]. The degree of damage to the respiratory tract epithelium and the level of cell proliferation that develops accordingly are determined by the damaging volume and duration of action of a particular pathological factor. Due to the relatively low level of proliferative activity of some cells of the epithelial layer of the respiratory system, they are called a slowly renewing tissue system in many literatures. An example of this is the proliferation of Clara cells, because their regeneration in the trachea of white mice requires about one and a half days. But often, when the integrity of the epithelial layer of the trachea and bronchioles is violated, cells that are not damaged by the impact are activated and begin to actively divide. It is for this reason that Clara cells are considered stem cells of the mucous epithelium. The peculiarity of secretory cells of the epithelium is that they do not lose the ability to produce mucous -secretory substances during mitosis due to epidermoid differentiation. The process of epidermoid differentiation in the epithelium of the trachea and bronchi is considered a normal state and is a general reaction of the body to any damage (thermal and mechanical, cold ) [4,5,6]. Thus, the study of the morphofunctional features of the structural components of the airways, which are a barrier between the internal environment of the body and external factors, will allow us to come closer to understanding the pathogenetic mechanisms of inflammation, chronization of the inflammatory process. Studies of these mechanisms, especially in the proliferative stage of inflammation of the upper respiratory tract will allow us to develop approaches that effectively control the development of possible complications associated with the ascent of the infectious agent and obstruction of the airways.

**The aim of the study** is to establish the characteristics of the development of the proliferative stage of aseptic inflammation of the upper respiratory tract under experimental conditions, the regenerative potential of the epithelium of the tracheal mucosa, and the mechanisms of chronicity of the inflammatory reaction.

**Materials and methods.** The first control group consisted of 6 intact animals, which were kept in a vivarium close to clinical conditions, observing sanitary rules at normal laboratory temperature during the entire experiment. The second control group consisted of 24 sham-operated animals, in which, under general anesthesia, the neck area was opened by a midline incision up to the ante-

rior wall of the trachea and, after revision, the wound was tightly sutured layer by layer. The experimental group consisted of 30 animals, in which the model of aseptic inflammation of the trachea was reproduced according to the method developed by us [1]. Under intravenous anesthesia ( xylazine at a dose of 0.2 ml/kg), the animal was fixed on a special operating table with its back down. The anterior surface of the animal's neck was treated with a disinfectant solution. The fur in the surgical field was cleaned and treated with iodine. A midline skin incision approximately 3.0 cm long was made in the area of the upper third of the neck. The wound was opened by sharp and blunt means, while the anterior wall of the trachea was exposed to the wound surface. A plastic irrigation plate measuring 0.5 x 0.5 cm was applied to the anterior wall of the trachea. The tracheal wall was irrigated with ethyl chloride solution through the opening (false operation using 0.9% sodium chloride solution) until white frost appeared. After the frost disappeared, the tracheal wall acquired a pronounced pallor caused by ischemia of this section of the tracheal wall. The postoperative wound was tightly sutured layer by layer. The wound was treated with an antiseptic.

**Results.** Morphometric analysis of the structural organization of the tracheal wall during its aseptic inflammation showed the presence of significant remodeling in comparison with both intact and sham-operated animals depending on the terms of the experiment. The changes primarily concerned the structural components of the mucous membrane. Thus, in the animal of the experimental group on the 5th day after reproducing the aseptic inflammation model, the specific volume of ciliated cells of the tracheal mucosa was  $9.8 \pm 2.22\%$ , which is 37.9% lower than the values of the intact and control groups of animals. The volume of the integumentary epithelium increased by 13.1% and amounted to  $40.5 \pm 2.78\%$  and is 14.1% higher than the values of the control group of animals. By this time of the study, the specific volume of basal epithelial cells increased significantly to  $21.2 \pm 1.65\%$ , which is almost twice as high as the corresponding values of both intact and sham-operated groups of animals (Table 1). Morphometric analysis of the structural components of the submucosal layer of the tracheal wall of experimental animals by this time did not reveal any significant changes. Only a slight decrease in the specific volume of glandular cells and functioning microvessels was established (Table 2).

In the experimental group animals, on the 7th day after the reproduction of the aseptic inflammation model, the specific volume of ciliated cells of the tracheal mucosa was  $9.7 \pm 1.13\%$ , which is 38.6% lower than the values of the intact and 32.6% lower than the values of the control group of animals. Also, by this time, the specific volume of goblet cells of the tracheal mucosa decreased and was  $6.6 \pm 0.26\%$ , which is 39.4% lower than the values of the intact and 34.6% lower than the values of the control group of animals. The increase in the volume of the integumentary epithelium by this time was insignificant and was  $36.4 \pm 2.79\%$ . By this time, the specific volume of basal epithelial cells significantly increased -  $20.1 \pm 2.08\%$ , which is almost twice as high as the corresponding values of both the intact and control groups of animals. (Table 1).

**Table 1.** Comparative morphological indices of structural components of the mucous membrane of the tracheal wall of rabbits in the dynamics of aseptic inflammation, in %.

	V p.e.		V re		V bk		V bze	
	l/op	Experience	l/op	Experience	l/op	Experience	l/op	Experience
Day 5	35.5±3.04	40.5±2.78* **	15.8±2.22	9.8±2.22* **	10.5±1.19	9.5±1.11	9.2±1.43	21.2±1.65* **
Day 7	34.4±2.79	36.4±2.09	14.4 ± 1.13	9.7 ± 1.13 * **	10.1±0.65	6.6±0.26* **	9.9±1.68	20.1±2.08* **
Day 14	34.3±1.76	31.5±2.67	14.1± 0.94	7.9 ± 0.57 * **	10.7±0.42	3.5±0.19* **	9.5±0.96	20.1±1.75* **
Intact	35.8±1.72		15.8±1.09		10,9 ±1,14		9.1±0.85	

Notes: Vpe - covering epithelium of the mucous membrane of the trachea; Vre - ciliated epithelium; Vбк - goblet cells; Vбзэ - basal epithelial cells.

\* - results are reliable in relation to the indicators of intact rabbits (p<0.05)

\*\* - the results are reliable in relation to the indicators of sham-operated rabbits (p<0.05)

**Table 2.** Comparative morphological indices of structural components of the submucosal layer of the tracheal wall of rabbits in the dynamics of aseptic inflammation, in %.

	V sp		V f		V with		V st	
	l/op	Experience	l/op	Experience	l/op	Experience	l/op	Experience
Day 5	64.5±2.75	59.5±2.47	7.7±0.61	7.2±0.41*	15.3±2.34	10.5±1.96**	41.4±3.48	42.4±2.39
Day 7	65.6±4.18	63.6±4.71	9.9±0.67	6.9±0.53* **	17.1± 2.56 *	9.8± 2.12 *	45.4±3.60	46.9±3.31
Day 14	65.7± 3.89	68.5±3.54	10.4±0.98	6.3±1.14* **	15.2± 1.01	8.5±1.28* **	44.1±2.86	53.7 ±3.93* **
Intact	64.2±2.62		9.3±0.81		12.5±0.93		42.4±1.74	

Notes: Vsp - connective tissue of the tracheal mucosa; Vж - glands; Vco - microvessels; Vстрэ - stromal elements.

\* - results are reliable in relation to the indicators of intact rabbits (p<0.05)

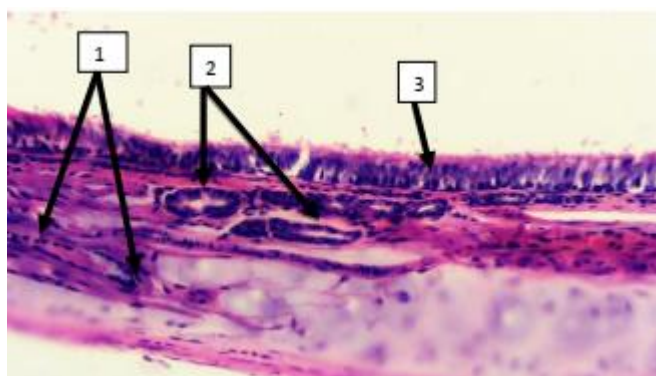
\*\* - the results are reliable in relation to the indicators of sham-operated rabbits (p<0.05)

When studying the structural components of the submucosal layer of the tracheal wall of experimental animals by this time, a decrease in the specific volume of glandular cells was found -  $6.9 \pm 0.53\%$ , which is significantly lower than the corresponding values of intact animals - by 25.8% and sham-operated animals - by 30.3%. For this period, the highest difference between the examined groups was expressed in the specific volume of functioning microvessels. Thus, their specific volume was equal to  $9.8 \pm 2.12\%$ , which was lower than the corresponding values of intact animals by 21.6%. In the group of sham-operated animals, this indicator was equal to  $17.1 \pm 2.56\%$ , which was 42.7% higher than the values of the experimental animals by this time of the study. Other studied parameters did not differ significantly from the values of intact animals (Table 2).

On the 14th day after reproduction of the aseptic inflammation model in the experimental group animals, the specific volume of ciliated cells of the tracheal mucosa was  $7.9 \pm 0.57\%$ , which was 50% lower than the values of the intact animals. Also, in this group, the proportion of secretory active goblet cells significantly decreased to  $3.5 \pm 0.19\%$ , which is 67.3% lower than the values of the intact animals. In the group of sham-operated animals, the specific volume of ciliated and goblet cells of the mucosa did not differ significantly from the values of the intact animals. By this time of the study, the specific volume of basal epithelial cells significantly increased -  $20.1 \pm 1.75\%$ , which is almost twice as high as the corresponding values of the intact and sham-operated animals. Remodulation of the structural components of the submucosal layer of the tracheal wall of the experimental animals reached its maximum values by this time. Thus, on the 14th day of the

experiments, compared to the intact group of animals, the volume of stromal elements of the tracheal wall in the experimental group of animals increased by 26.6% and amounted to  $53.7 \pm 3.93\%$ . Also, a noticeable decrease in the specific volume of submucous glandular cells and functioning microvessels was revealed. The specific volume of submucous glandular cells was 32.2% less than the corresponding values of intact animals and was equal to  $6.3 \pm 1.14\%$ . The specific volume of functioning microvessels was 32.0% less than the corresponding values of intact animals and was  $8.5 \pm 1.28\%$ . Thus, aseptic inflammation under the action of ethyl chloride, which causes cold necrosis, leads to a significant redistribution of the cellular composition, namely, remodeling of the structural components of the mucous and submucous layers of the tracheal wall. The proportion of goblet cells and ciliated epithelium, submucous glandular cells and functioning microvessels decreases. At the same time, the proportion of basal epithelial cells and stromal elements increases. All this leads to a significant decrease in the protective capabilities of the tracheal mucosa, its submucosal layer. Goblet cells in the tracheal wall accumulate mucinogenic granules, which, when combined with water, form mucin, the main part of saliva. As a result, these cells acquire the shape of a goblet. Then the goblet cells secrete the mucin accumulated in the tracheal cavity, as a result of which the cell returns to its previous state and becomes prismatic, and the cycle is repeated. Mucin secreted from the goblet cells into the tracheal cavity performs moisturizing and protective functions. These data allow us to come closer to understanding the complex pathogenetic mechanisms of pathology progression, the impact on which would allow us to effectively control the proliferative stage of the in-

flammatory process, which was characterized by uncontrolled activation of the transforming growth factor, the development of fibrosis. Moreover, fibrosis developed not only in the lesion, but also in the perifocal areas. Finding ways to inhibit excessive activation of stromal element proliferation could possibly prevent a decrease in the protective properties of the respiratory tract mucosa and, as a consequence, the chronicity of the process. In general, the above-described changes characterize the progression of processes of characteristic reorganization of the morphological structure of the trachea with a significant decrease in the protective capabilities of the tracheal mucosa and its submucosal layer. The morphological picture of the tracheal wall on the 5th day after modeling the inflammation is characterized by some compaction of the epithelial lining with partial atrophy of the ciliated epithelium. The submucosal layer is somewhat expanded due to interstitial edema, loosening of collagen fibers. Venous hyperemia of microvessels is revealed. Individual vessels are obstructed by aggregates of formed elements, mainly aggregates of erythrocytes.

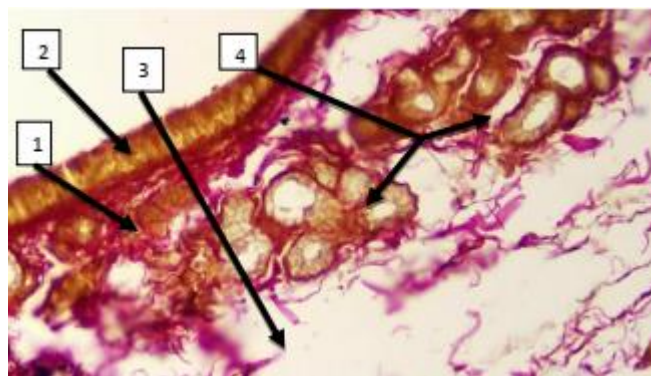


**Fig. 1.** Tracheal mucosa of an intact rabbit.

Pseudomoderate epithelial lining (3), clearly defined ciliated layer. Submucosa is organized, blood vessel walls (2) are without edema. Mucocele cells (1) are normal. Hematoxylin and eosin staining. Magnification: 10×100

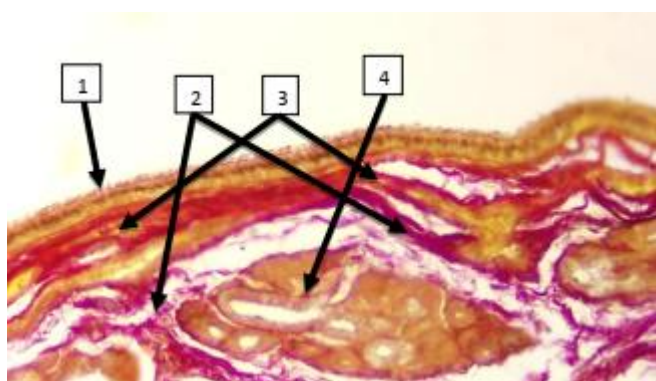
On the 7th day of aseptic inflammation, the compaction of the epithelial lining and atrophy of the ciliated epithelium became more pronounced. Collagen fibers took the form of fibrous-collagen strands. Inflammatory hyperemia became predominantly venous, individual vessels were obstructed by aggregates of formed elements. Edema of the submucosal layer was pronounced. The 14th day of aseptic inflammation was characterized by an almost complete absence of ciliated epithelium, organization of fibrous-collagen fibers of the submucosal layer. The walls of blood vessels were thickened due to edema. Hypo- and atrophy of glandular structures were noted.

Thus, damaged bronchial epithelial cells initiate activation of the epithelial- mesenchymal trophic unit of the stroma. Activation of stromal elements is considered a key mechanism of airway wall remodeling. The number of mesenchymal stromal cells increased proportionally to the thickening and compaction of the reticular collagen layer. Such structural remodeling of the tracheal wall with disproportionate growth of connective tissue elements disrupts the trophism of all layers of the tracheal wall, primarily the mucous membrane.

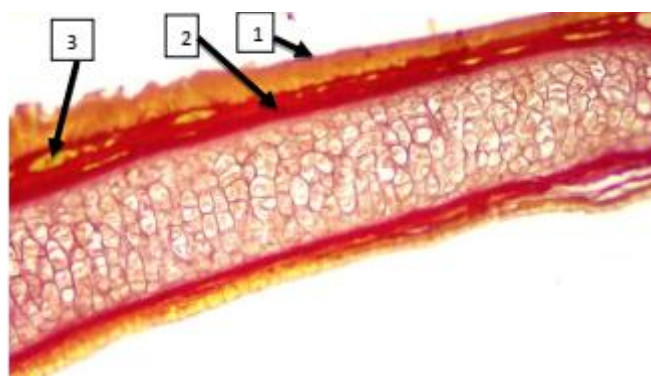


**Fig. 2.** Mucous membrane of the rabbit trachea on the 5th day of aseptic inflammation.

Thickening of the epithelial lining (2) with partial atrophy of the ciliated epithelium. The submucosal layer is thickened by collagen (1), somewhat expanded by interstitial edema (3). Venous hyperemia of microvessels. Individual vessels are obstructed by aggregates (4). Van Gieson staining. Magnification: 10×100



**Fig. 3.** Mucous membrane of the rabbit trachea on the 7th day of aseptic inflammation. 1-Condensation of the epithelial lining, atrophy of the ciliated epithelium. 2-Edema and loosening of the stromal elements. 3-Condensation of collagen fibers and formation of collagen strands in the subepithelial zone. 4-Venous hyperemia of microvessels



**Fig. 4.** Mucous membrane of the trachea of a rabbit on the 14th day of aseptic inflammation.

Compaction of the epithelial lining, ciliated epithelium is practically not determined (1). Fibrous-collagen fibers of the submucosal layer are tightly organized (2). Hypo- and atrophy of subepithelial glandular structures (3). Van Gieson staining. Magnification: 10×100

**Discussion.** Our studies have shown that the study of the quantitative ratios of epithelial components and the level of regenerative activity of the multi-row ciliated epithelium in the tracheal wall made it possible to determine a number of their specific characteristics at different times after aseptic injury. The number of ciliated cells, glandular and goblet cells decreased on the 14th day of the experiment compared to the indicators in the early stages after aseptic injury in animals of the experimental group. An increase in cellular density in the epithelial tissue can cause the death of some of its cells. On the 7th and 14th days of our experiment, thickened bundles of collagen fibers and lymphoid infiltration zones were detected in the mucous membrane of the tracheal wall of animals of the experimental group. According to the results of many studies, intracellular regeneration plays a key role in the restoration of the ciliated epithelium itself. The reaction of warm-blooded animals to the cold factor is a broad subject of modern research and is widely studied in connection with their negative impact on the respiratory system. Hyperreactivity of the respiratory tract develops due to disruption of the integrity of the epithelium of the mucous membrane of the respiratory tract. In the tissues, under the influence of cold air flow, accumulation of biologically active substances is observed. At the same time, in the mucous membrane of the bronchi, as the pathological process increases from the 5th to the 14th day, areas of its desquamation, depletion of goblet cells, destruction of cell cilia are revealed. It is known that one of the morphological manifestations of inflammation of the airways is mucous membrane edema. It has been established that in the bronchial epithelium, intercellular gaps expand, especially between basal cells. Intercellular spaces are filled with a homogeneous substance of low electron density. Morphometric analysis of the structural organization of the tracheal wall during its aseptic inflammation showed the presence of significant remodulation both in comparison with intact and sham-operated animals, depending on the timing of the experiment. The changes primarily concerned the structural components of the mucous membrane. Thus, in the experimental group of animals, the decrease in the volume of ciliated cells was 37.9%, compared with the results of intact animals on the 5th day of the experiment, and the decrease compared with the group of sham-operated animals was almost 38%. Compared with the results of intact animals on the 7th day of the experiment, the decrease in the volume of ciliated cells in the experimental group of animals was 38.6%, the decrease compared with the group of sham-operated animals was 32.6%. The highest decrease in the volume of ciliated cells was 50% compared with the indicators of intact animals, the decrease compared with the group of sham-operated animals was 44%, respectively, on the 14th day of the experiments. Also, the proportion of goblet cells in animals of the experimental group decreased, compared with the results of intact animals on the 5th day of the experiment, the decrease in the volume of goblet cells in animals of the experimental group was 12.8%, the decrease compared with the group of sham-operated animals was 9.5%. In the experimental group of animals, the volume of goblet cells decreased by 39.4% compared to the results of intact animals on the 7th day of the experiment, and the decrease compared to the group of sham-operated animals was 34.6%. The proportion of goblet cells in the experimental group of animals decreased

especially on the 14th day of the experiments. By this time, their volume decreased by 67.8% compared to the same indicator of intact animals, and the decrease compared to the group of sham-operated animals was almost 67.3%. The volume of basal epithelial cells at all studied times was more than 2 times higher than the values of both intact and sham-operated animals. For example, in the experimental group of animals, the volume of basal epithelial cells was 21.2%, and in intact animals on the 5th day of the experiment, the volume of basal epithelial cells was 9.2%, in sham-operated animals, the volume of basal epithelial cells was 9.1%. In general, the above-described changes characterize the progression of the processes of characteristic reorganization of the morphological structure of the trachea with a significant decrease in the protective capabilities of the tracheal mucosa and its submucosal layer. During morphometry of the elements of the submucosal layer, pronounced shifts in the experimental group of animals were noted in the volume of submucosal glands, microvessels and stromal elements. Thus, in the animal experimental group, the volume of glands was significantly lower than the intact values by 22.6%, compared with similar indicators of intact animals on the 5th day of the experiment, and the decrease compared with the group of sham-operated animals was almost insignificant. Compared with similar indicators of intact animals on the 7th day of the experiment, the decrease in the volume of glands in animals of the experimental group was 25.8%, the decrease compared with the group of sham-operated animals was 30.3%. The highest decrease in the volume of glands was 32.2% compared to the intact animals, the decrease compared to the group of sham-operated animals was 39.4%, respectively, on the 14th day of the experiments. In the experimental group of animals, the volume of microvessels also significantly decreased. Compared with similar indicators of intact animals on the 5th day of the experiment, the decrease in the volume of microvessels in animals of the experimental group was 16%, the decrease compared to the group of sham-operated animals was 31.4%. On the 7th day of the experiment, the decrease in the volume of microvessels in animals of the experimental group was 21.6%, compared with similar indicators of intact animals, the decrease compared to the group of sham-operated animals was 42.7%.

The most pronounced decrease in the volume of microvessels was noted on the 14th day of the experiments, when the relative volume of microvessels was equal to  $8.5 \pm 1.28\%$ , which was 32% lower than the values of intact animals, the decrease compared to the group of sham-operated animals was 42.7%. The volume of stromal elements increased significantly, primarily due to basal epithelial cells and collagens of the proper connective tissue plate of the tracheal mucosa. Thus, on the 14th day of the experiments, compared with the intact group of animals, the volume of stromal elements of the tracheal wall in the experimental group of animals increased by 26.6% and amounted to 53.7%. In general, the above-described changes characterize the progression of the processes of characteristic restructuring of the morphological structure of the trachea with a significant decrease in the protective capabilities of the tracheal mucosa and its submucosal layer [4].

**Conclusion.** A method for modeling acute inflammation of the upper respiratory tract has been

developed and implemented in practice. The essence of the method consists of the effect on the anterior wall of the trachea with ethyl chloride through a plate with a hole of constant size (5x10 mm) until white frost appears. Remodulation of the tracheal wall components during aseptic inflammation is characterized by a decrease in the adaptive and protective activity of the epithelium, a decrease in the number of secretory-active cells of the mucous membrane, an increase in connective tissue elements in the form of collagen fibers in the submucosal layer.

Disproportionate proliferation of connective tissue elements and reduction of microvessels causes structural reorganization of the tracheal wall and disrupts the trophism of all its layers, primarily the mucous membrane. This reduces the ability to re-epithelialize, weakens the extracellular matrix and increases the predisposition to chronicity of many respiratory pathologies.

#### Literature:

1. Lebedeva A.I., Muslimov S.A., Musina L.A., // Experimental modeling of the process of chronic inflammation and fibrosis. Biomedicine No. 4, 2013, pp. 114–123
2. Namakonova V.S., Krasavina N.P., Tseluiko S.S., // Effect of low temperatures on the epithelium of the respiratory tract and lipid peroxidation reactions in the lungs of rats of different ages., Bulletin of Physiology and Pathology of Respiration. 2017. - No. 63. - Pp. 61-65
3. Samyeva G. U., Abdirashidova G. A., Sobirova Sh. B. Prognostic value of the cytokine spectrum and their changes in primary and recurrent laryngotracheitis in children // innovative research: problems of implementing results and directions of development. - 2017. - P. 103.
4. Samyeva G. U., Rustamova G. R. INFECTIOUS AGENTS IN CHRONIC TONSILLITIS IN CHILDREN // Innovative research in the modern world: theory and practice. - 2022. - V. 1. - No. 24. - P. 386-387.
5. Samyeva G. U., Karabaev H. E. Clinical features of the course of recurrent stenosing laryngotracheitis in children // Academic Journal of Western Siberia. - 2013. - V. 9. - No. 2. - P. 6-6.
6. Olimzhonova F. O., Samyeva G. U., Shadiev S. S. Prognostic value of the salivary cytokine spectrum and their changes in acute and chronic recurrent stomatitis in children // Concepts of fundamental and applied scientific research: Collection of articles based on the results of the International Scientific and Practical Conference (Ufa, December 9, 2017)./in 6 parts. Part 6. – 2017. – P. 83.
7. Samyeva G., Karabaev H. Modern approaches to diagnostics and treatment of acute stenosing recurrent laryngotracheitis in children against the background of acute respiratory viral infections // Journal of the Vestnik Vrachei. - 2012. - V. 1. - No. 3. - P. 167-172.
8. Bl o be, GC, WP Schiemann , HF // R o l e o f trans f o r m i n g g r o w t h f a c t o r b e t a i n h u m a n d i s e a s e. Nat. Engl. J o r. Med. – 2000. – V o l. 342. – Pp.1350–1358.
9. Hasegawa M., Fujim o t o M., Hamaguchi Y. et all. // Use f serum Clara cell 16kDa (CC16) levels as ap potential

indicat o r o f active pulm o n a r y f i b r o s i s i n s y s t e m i c s c l e r o s i s. J o r. Rheumat o l. 2011; 38(5): pp.877–884.

10. JUNB / AP-1 c o n t r o l s I F-  $\gamma$  during inflammat o r y liver disease / MK Th o m s e n , L. Bakiri , SC Hasenfuss et al. // J o r n a l o f Clinical Invest. – 2013. – No. 123 (12). – pp. 5258-5268.
11. About ettgen HC, Geha RS // IgE regulati o n and r o l e s i n a s t h m a p a t h o g e n e s i s. J o r. Allergy Clin. Immun o l o g y . 2001; 107(3): pp.429–440.
12. Takana H, In o u e K., Yanagisawa R., et all. // P r o t e c t i v e r o l e o f m e t a l l o t h i o n e i n a c u t e l u n g i n j u r y i n d u c e d b y b a c t e r i a l e n d o t o x i n . Th o r a x . 2004. V o l. 59 (12): P.1057–62
13. Rizaev J. A., Vohidov E. R., Nazarova N. S. The importance of the clinical picture and development of the condition of periodont tissue diseases in pregnant women //Central Asian Journal of Medicine. – 2024. – №. 2. – С. 85-90.
14. Rizaev J. A., Nazarova N. S., Vohidov E. R. Homilador ayollarda parodont kasalliklari rivojlanishining patogenetik jihatlari //Журнал гуманитарных и естественных наук. – 2024. – №. 11 [2]. – С. 104-107.
15. Rizaev J. A., Rizaev E. A., Akhmadaliev N. N. Current View of the Problem: A New Approach to Covid-19 Treatment // Indian Journal of Forensic Medicine & Toxicology. – 2020. – Т. 14. – №. 4.
16. Rizaev J. A., ugli Sattorov B. B., Nazarova N. S. Analysis of the scientific basis for organizing dental care for workers in contact with эпоху resin //Журнал гуманитарных и естественных наук. – 2024. – №. 15. – С. 280-283.

#### **СТРУКТУРНАЯ РЕМОДУЛЯЦИЯ И МОРФОМЕТРИЧЕСКИЙ АНАЛИЗ ЭЛЕМЕНТОВ СТЕНКИ ТРАХЕИ ПРИ ЕЕ АСЕПТИЧЕСКОМ ВОСПАЛЕНИИ**

*Самиева Г.У., Собирова Ш.Б., Бахранова М.Ш.*

**Резюме.** Воспаление слизистой оболочки респираторного тракта сопровождается патоморфологическим процессом на клеточном, тканевом и иммунном уровнях организма. В исследованиях, направленных на изучение воспалительного процесса наиболее актуальным является разработка вопросов патогенеза поражения тканей, прогнозирование возможных осложнений и разработка принципов и методов их предупреждения. Основной системой, реализующей воспалительные реакции, является система крови, ее ответ на действие повреждающего агента. Этим и определяется целесообразность профилактики и лечения воспаления путем стимуляции защитных сил организма путем усиленной продукции активных лейкоцитов защитными функциями.

**Ключевые слова:** асептическое воспаление, структурная ремодуляция, эпидермоидная дифференцировка.