

CRR
JOURNAL
OF CARDIORESPIRATORY RESEARCH

ISSN 2181-0974
DOI 10.26739/2181-0974
Impact Factor SJIF 2022: 5.937

Journal of

**CARDIORESPIRATORY
RESEARCH**



Volume 5, Issue 2

2024

МИНИСТЕРСТВО ЗДРАВООХРАНЕНИЯ
РЕСПУБЛИКИ УЗБЕКИСТАН

Журнал кардиореспираторных исследований

JOURNAL OF CARDIORESPIRATORY RESEARCH

Главный редактор: Э.Н.ТАШКЕНБАЕВА

Учредитель:

Самаркандский государственный
медицинский университет

Tadqiqot.uz

Ежеквартальный
научно-практический
журнал

ISSN: 2181-0974
DOI: 10.26739/2181-0974



N° 2
2024

Главный редактор:

Ташкенбаева Элеонора Негматовна

доктор медицинских наук, заведующая кафедрой внутренних болезней №2 Самаркандского Государственного медицинского университета, председатель Ассоциации терапевтов Самаркандской области. <https://orcid.org/0000-0001-5705-4972>

Заместитель главного редактора:

Хайбулина Зарина Руслановна

доктор медицинских наук, руководитель отдела биохимии с группой микробиологии ГУ «РСНПМЦХ им. акад. В. Вахидова» <https://orcid.org/0000-0002-9942-2910>

ЧЛЕНЫ РЕДАКЦИОННОЙ КОЛЛЕГИИ:

Аляви Анис Лютфуллаевич

академик АН РУз, доктор медицинских наук, профессор, Председатель Ассоциации Терапевтов Узбекистана, Советник директора Республиканского специализированного научно-практического центра терапии и медицинской реабилитации (Ташкент) <https://orcid.org/0000-0002-0933-4993>

Бокерия Лео Антонович

академик РАН, доктор медицинских наук, профессор, Президент научного центра сердечно-сосудистой хирургии им. А.Н. Бакулева (Москва), <https://orcid.org/0000-0002-6180-2619>

Курбанов Равшанбек Давлетович

академик АН РУз, доктор медицинских наук, профессор, Советник директора Республиканского специализированного научно-практического медицинского центра кардиологии (Ташкент), <https://orcid.org/0000-0001-7309-2071>

Шкляев Алексей Евгеньевич

д.м.н., профессор, ректор Федерального государственного бюджетного образовательного учреждения высшего образования «Ижевская государственная медицинская академия» Министерства здравоохранения Российской Федерации

Michał Tendera

профессор кафедры кардиологии Верхнесилезского кардиологического центра, Силезский медицинский университет в Катовице, Польша (Польша) <https://orcid.org/0000-0002-0812-6113>

Покушалов Евгений Анатольевич

доктор медицинских наук, профессор, заместитель генерального директора по науке и развитию сети клиник «Центр новых медицинских технологий» (ЦНМТ), (Новосибирск), <https://orcid.org/0000-0002-2560-5167>

Зуфаров Миржамол Мирумарович

доктор медицинских наук, профессор, руководитель отдела ГУ «РСНПМЦХ им. акад. В. Вахидова» <https://orcid.org/0000-0003-4822-3193>

Акилов Хабибулла Атауллаевич

доктор медицинских наук, профессор, Директор Центра развития профессиональной квалификации медицинских работников (Ташкент)

Абдиева Гулнора Алиевна

PhD, ассистент кафедры внутренних болезней №2 Самаркандского государственного медицинского университета, <https://orcid.org/0000-0002-6980-6278> (ответственный секретарь)

Ризаев Жасур Алимджанович

доктор медицинских наук, профессор, Ректор Самаркандского государственного медицинского университета, <https://orcid.org/0000-0001-5468-9403>

Зиядуллаев Шухрат Худойбердиевич

доктор медицинских наук, доцент, проректор по научной работе и инновациям Самаркандского Государственного медицинского университета <https://orcid.org/0000-0002-9309-3933>

Джан Ковак

Профессор, председатель Совета Европейского общества кардиологов по инсульту, руководитель специализированной кардиологии, заведующий отделением кардиологии, кардио- и торакальной хирургии, консультант-кардиолог, больница Гленфилд, Лестер (Великобритания)

Сергио Бернардини

Профессор клинической биохимии и клинической молекулярной биологии, главный врач отдела лабораторной медицины, больница Университета Тор Вергата (Рим, Италия)

Ливерко Ирина Владимировна

доктор медицинских наук, профессор, заместитель директора по науке Республиканского специализированного научно-практического медицинского центра фтизиатрии и пульмонологии Республики Узбекистан (Ташкент) <https://orcid.org/0000-0003-0059-9183>

Цурко Владимир Викторович

доктор медицинских наук, профессор Первого Московского государственного медицинского университета им. И.М. Сеченова (Москва) <https://orcid.org/0000-0001-8040-3704>

Тригулова Раиса Хусановна

Доктор медицинских наук, руководитель лаборатории превентивной кардиологии, ведущий научный сотрудник лаборатории ИБС и атеросклероза. Республиканский специализированный научно-практический медицинский центр кардиологии (Ташкент) ORCID- 0000-0003-4339-0670

Тураев Феруз Фатхуллаевич

доктор медицинских наук, Директор Республиканского специализированного научно-практического медицинского центра эндокринологии имени академика Ю.Г. Туракулова

Bosh muharrir:

Tashkenbayeva Eleonora Negmatovna

*tibbiyot fanlari doktori, Samarqand davlat tibbiyot universiteti 2-sonli ichki kasalliklar kafedrasini mudiri,
Samarqand viloyati vrachlar uyushmasi raisi.
<https://orsid.org/0000-0001-5705-4972>*

Bosh muharrir o'rinbosari:

Xaibulina Zarina Ruslanovna

*tibbiyot fanlari doktori, "akad V. Vohidov nomidagi RIJM davlat institutining mikrobiologiya guruhi
bilan biokimyo kafedrasini mudiri" <https://orcid.org/0000-0002-9942-2910>*

TAHRIRIYAT A'ZOLARI:

Alyavi Anis Lyutfullayevich

*O'zbekiston Respublikasi Fanlar akademiyasining akademigi, tibbiyot fanlari doktori, professor,
O'zbekiston Terapevtlar uyushmasi raisi, Respublika ixtisoslashtirilgan ilmiy va amaliy tibbiy terapiya markazi va tibbiy reabilitatsiya direktori maslahatchisi (Toshkent), <https://orcid.org/0000-0002-0933-4993>*

Bockeria Leo Antonovich

*Rossiya fanlar akademiyasining akademigi, tibbiyot fanlari doktori, professor, A.N. Bakuleva nomidagi yurak-qon tomir jarrohligi ilmiy markazi prezidenti (Moskva)
<https://orcid.org/0000-0002-6180-2619>*

Kurbanov Ravshanbek Davlatovich

*O'zbekiston Respublikasi Fanlar akademiyasining akademigi, tibbiyot fanlari doktori, professor,
Respublika ixtisoslashtirilgan kardiologiya ilmiy-amaliy tibbiyot markazining direktor maslahatchisi (Toshkent)
<https://orcid.org/0000-0001-7309-2071>*

Shklyayev Aleksey Evgenievich

Tibbiyot fanlari doktori, professor, Rossiya Federatsiyasi Sog'liqni saqlash vazirligining "Izhevsk davlat tibbiyot akademiyasi" Federal davlat byudjeti oliy ta'lim muassasasi rektori

Mixal Tendera

*Katovitsadagi Sileziya Tibbiyot Universiteti, Yuqori Sileziya Kardiologiya Markazi kardiologiya kafedrasini professori (Polsha)
<https://orcid.org/0000-0002-0812-6113>*

Pokushalov Evgeniy Anatolevich

tibbiyot fanlari doktori, professor, "Yangi tibbiy texnologiyalar markazi" (YTTM) klinik tarmog'ining ilmiy ishlar va rivojlanish bo'yicha bosh direktorining o'rinbosari (Novosibirsk) <https://orcid.org/0000-0002-2560-5167>

Zufarov Mirjamol Mirumarovich

tibbiyot fanlari doktori, professor, "akad V. Vohidov nomidagi RIJM davlat muassasasi" bo'limi boshlig'i" <https://orcid.org/0000-0003-4822-3193>

Akilov Xabibulla Ataulayevich

tibbiyot fanlari doktori, professor, Tibbiyot xodimlarining kasbiy malakasini oshirish markazi direktori (Toshkent)

Abdiyeva Gulnora Aliyevna

Samarqand davlat tibbiyot universiteti 2-sonli ichki kasalliklar kafedrasini assistenti, PhD (mas'ul kotib)

Rizayev Jasur Alimjanovich

*tibbiyot fanlari doktori, professor,
Samarqand davlat tibbiyot universiteti rektori
<https://orcid.org/0000-0001-5468-9403>*

Ziyadullayev Shuxrat Xudoyberdiyevich

*tibbiyot fanlari doktori, dotsent,
Samarqand davlat tibbiyot universitetining fan va innovatsiyalar bo'yicha prorektori (Samarqand)
<https://orcid.org/0000-0002-9309-3933>*

Jan Kovak

Yevropa kardiologiya jamiyati insulti kengashi raisi, 2017 yildan buyon ixtisoslashtirilgan kardiologiya kafedrasini rahbari, kardiologiya, yurak va torakal jarrohlik kafedrasini mudiri, maslahatchi kardiolog Glenfild kasalxonasi, Lester (Buyuk Britaniya)

Sergio Bernardini

Klinik biokimyo va klinik molekulyar biologiya bo'yicha professor - Laboratoriya tibbiyoti bo'limi bosh shifokori – Tor Vergata universiteti kasalxonasi (Rim-Italiya)

Liverko Irina Vladimirovna

*tibbiyot fanlari doktori, professor,
Respublika ixtisoslashtirilgan fiziologiya va pulmonologiya ilmiy-amaliy tibbiyot markazining ilmiy ishlar bo'yicha direktor o'rinbosari (Toshkent)
<https://orcid.org/0000-0003-0059-9183>*

Surko Vladimir Viktorovich

*tibbiyot fanlari doktori, professori I.M. Sechenov nomidagi Birinchi Moskva Davlat tibbiyot universiteti (Moskva)
<https://orcid.org/0000-0001-8040-3704>*

Trigulova Raisa Xusainovna

*Tibbiyot fanlari doktori, Profilaktik kardiologiya laboratoriyasi mudiri, YuK va ateroskleroz laboratoriyasining yetakchi ilmiy xodimi. Respublika ixtisoslashtirilgan kardiologiya ilmiy-amaliy tibbiyot markazi (Toshkent)
ORCID- 0000-0003-4339-0670*

Turayev Feruz Fatxullayevich

*tibbiyot fanlari doktori, akademik Y.X.To'raqulov nomidagi Respublika ixtisoslashtirilgan endokrinologiya ilmiy amaliy tibbiyot markazi direktori
<https://orcid.org/0000-0002-1321-4732>*

Chief Editor:

Tashkenbaeva Eleonora Negmatovna

Doctor of Medical Sciences, Head of the Department of Internal Diseases No. 2 of the Samarkand State Medical University, Chairman of the Association of Physicians of the Samarkand Region.
<https://orcid.org/0000-0001-5705-4972>

Deputy Chief Editor:

Xaibulina Zarina Ruslanovna

Doctor of Medical Sciences, Head of the Department of Biochemistry with the Microbiology Group of the State Institution "RSSC named after acad. V. Vakhidov", <https://orcid.org/0000-0002-9942-2910>

MEMBERS OF THE EDITORIAL BOARD:

Alyavi Anis Lutfullaevich

Academician of the Academy of Sciences of the Republic of Uzbekistan, Doctor of Medical Sciences, Professor, Chairman of the Association of Physicians of Uzbekistan, Advisor to the Director of the Republican Specialized Scientific - Practical Center of Therapy and Medical Rehabilitation (Tashkent)
<https://orcid.org/0000-0002-0933-4993>

Bockeria Leo Antonovich

Academician of the Russian Academy of Sciences, Doctor of Medical Sciences, Professor, President of the Scientific Center for Cardiovascular Surgery named after A.N. Bakuleva (Moscow)
<https://orcid.org/0000-0002-6180-2619>

Kurbanov Ravshanbek Davletovich

Academician of the Academy of Sciences of the Republic of Uzbekistan, Doctor of Medical Sciences, Professor, Advisor to the Director Republican Specialized Scientific and Practical Medical Center of Cardiology, (Tashkent)
<https://orcid.org/0000-0001-7309-2071>

Shklyayev Aleksey Evgenievich

Doctor of Medical Sciences, Professor, Rector of the Federal State Budgetary Educational Institution of Higher Education "Izhevsk State Medical Academy" of the Ministry of Health of the Russian Federation

Michal Tendera

Professor of the Department of Cardiology, Upper Silesian Cardiology Center, Silesian Medical University in Katowice, Poland (Poland)
<https://orcid.org/0000-0002-0812-6113>

Pokushalov Evgeny Anatolyevich

Doctor of Medical Sciences, Professor, Deputy Director General for Science and Development of the Clinic Network "Center for New Medical Technologies" (CNMT), (Novosibirsk)
<https://orcid.org/0000-0002-2560-5167>

Akilov Xabibulla Ataullovich

Doctor of Medical Sciences, Professor, Center for the development of professional qualifications of medical workers (Tashkent)

Abdieva Gulnora Alievna

PhD, assistant of the Department of Internal Diseases No. 2 of the Samarkand State Medical University
<https://orcid.org/0000-0002-6980-6278>
(Executive Secretary)

Rizaev Jasur Alimjanovich

Doctor of Medical Sciences, Professor, Rector of the Samarkand State Medical University
<https://orcid.org/0000-0001-5468-9403>

Ziyadullaev Shuhrat Khudoyberdievich

Doctor of Medical Sciences, Associate Professor, Vice-Rector for Science and Innovation of the Samarkand State Medical University (Samarkand)
<https://orcid.org/0000-0002-9309-3933>

Jan Kovac

Professor Chairman, European Society of Cardiology Council for Stroke, Lead of Specialised Cardiology, Head of Cardiology, Cardiac and Thoracic Surgery, Consultant Cardiologist, Glenfield Hospital, Leicester (United Kingdom)

Sergio Bernardini

Full Professor in Clinical Biochemistry and Clinical Molecular Biology - Head Physician of the Laboratory Medicine Unit- University of Tor Vergata Hospital (Rome-Italy)

Liverko Irina Vladimirovna

Doctor of Medical Sciences, Professor, Deputy Director for Science of the Republican Specialized Scientific and Practical Medical Center for Phthiology and Pulmonology of the Republic of Uzbekistan (Tashkent)
<https://orcid.org/0000-0003-0059-9183>

Zufarov Mirjamol Mirumarovich

Doctor of Medical Sciences, Professor, Head of the Department of the State Institution "RSNPMTSH named after acad. V. Vakhidov"
<https://orcid.org/0000-0003-4822-3193>

Tsurko Vladimir Viktorovich

Doctor of Medical Sciences, professor Of Moscow State Medical University by name I.M. Sechenov (Moscow)
<https://orcid.org/0000-0001-8040-3704>

Trigulova Raisa Khusainovna

Doctor of Medical Sciences, Head of the Laboratory of Preventive Cardiology, Leading Researcher of the Laboratory of IHD and Atherosclerosis. Republican Specialized Scientific and Practical Medical Center of Cardiology (Tashkent) ORCID- 0000-0003-4339-0670

Turaev Feruz Fatxullaevich

Doctor of Medical Sciences, Director of the Republican Specialized Scientific and Practical Medical Center of Endocrinology named after Academician Yu.G. Turakulova

Алимов Дониёр Анварович
доктор медицинских наук, директор
Республиканского научного центра
экстренной медицинской помощи

Янгиев Бахтиёр Ахмедович
кандидат медицинских наук,
директор Самаркандского филиала
Республиканского научного центра
экстренной медицинской помощи

Абдуллаев Акбар Хатамович
доктор медицинских наук, главный
научный сотрудник Республиканского
специализированного научно-
практического центра медицинской
терапии и реабилитации
<https://orcid.org/0000-0002-1766-4458>

Агабабян Ирина Рубеновна
кандидат медицинских наук, доцент,
заведующая кафедрой терапии ФПДО,
Самаркандского Государственного
медицинского института

Алиева Нигора Рустамовна
доктор медицинских наук, заведующая
кафедрой Госпитальной педиатрии №1
с основами нетрадиционной медицины
ТашПМИ

Исмаилова Адолат Абдурахимовна
доктор медицинских наук, профессор,
заведующая лабораторией
фундаментальной иммунологии
Института иммунологии геномики
человека АН РУз

Камалов Зайнитдин Сайфутдинович
доктор медицинских наук, профессор,
заведующий лабораторией
иммунорегуляции Института
иммунологии и геномики
человека АН РУз

Каюмов Улугбек Каримович
доктор медицинских наук, профессор,
заведующий кафедрой внутренних
болезней и телемедицины Центра
развития профессиональной
квалификации медицинских работников

Хусинова Шоира Акбаровна
кандидат философских наук, доцент,
заведующая кафедрой общей практики,
семейной медицины ФПДО
Самаркандского Государственного
медицинского института

Шодиколова Гуландом Зикрияевна
д.м.н., профессор, заведующая
кафедрой внутренних болезней № 3
Самаркандского Государственного
Медицинского Института
(Самарканд)
<https://orcid.org/0000-0003-2679-1296>

Alimov Doniyor Anvarovich
tibbiyot fanlari doktori, Respublika
shoshilinch tibbiy yordam ilmiy
markazi direktori (Toshkent)

Yangiyev Baxtiyor Axmedovich
tibbiyot fanlari nomzodi,
Respublika shoshilinch tibbiy
yordam ilmiy markazining
Samarqand filiali direktori

Abdullayev Akbar Xatamovich
tibbiyot fanlari doktori, O'zbekiston
Respublikasi Sog'liqni saqlash
vazirligining "Respublika
ixtisoslashtirilgan terapiya va tibbiy
reabilitatsiya ilmiy-amaliy
tibbiyot markazi" davlat
muassasasi bosh ilmiy xodimi
<https://orcid.org/0000-0002-1766-4458>

Agababyan Irina Rubenovna
tibbiyot fanlari nomzodi, dotsent,
DKTF, terapiya kafedrasini mudiri,
Samarqand davlat tibbiyot instituti

Alieva Nigora Rustamovna
tibbiyot fanlari doktori, 1-sonli
gospital pediatriya kafedrasini mudiri,
ToshPTI

Ismoilova Adolat Abduraximovna
tibbiyot fanlari doktori, professor,
O'zbekiston Respublikasi Fanlar
akademiyasining Odam genomikasi
immunologiyasi institutining
fundamental immunologiya
laboratoriyasining mudiri

Kamalov Zaynitdin Sayfutdinovich
tibbiyot fanlari doktori, professor,
O'zbekiston Respublikasi Fanlar
akademiyasining Immunologiya va
inson genomikasi institutining
Immunogenetika laboratoriyasi mudiri

Qayumov Ulug'bek Karimovich
tibbiyot fanlari doktori, professor,
Tibbiyot xodimlarining kasbiy
malakasini oshirish markazi, ichki
kasalliklar va teletibbiyot kafedrasini
mudiri (Toshkent)

Xusinova Shoira Akbarovna
tibbiyot fanlari nomzodi, dotsent,
Samarqand davlat tibbiyot instituti
DKTF Umumiy amaliyot va oilaviy
tibbiyot kafedrasini mudiri (Samarqand)

Shodikulova Gulandom Zikriyaeвна
tibbiyot fanlari doktori, professor,
Samarqand davlat tibbiyot instituti 3-
ichki kasalliklar kafedrasini mudiri
(Samarqand)
<https://orcid.org/0000-0003-2679-1296>

Alimov Doniyor Anvarovich
Doctor of Medical Sciences, Director of
the Republican Scientific Center of
Emergency Medical Care

Yangiev Bakhtiyor Axmedovich
PhD, Director of Samarkand branch of
the Republican Scientific Center of
Emergency Medical Care

Abdullaev Akbar Xatamovich
Doctor of Medical Sciences,
Chief Researcher of the State Institution
"Republican Specialized Scientific and
Practical Medical Center for Therapy and
Medical Rehabilitation" of the Ministry of
Health of the Republic of Uzbekistan,
<https://orcid.org/0000-0002-1766-4458>

Agababyan Irina Rubenovna
PhD, Associate Professor, Head of the
Department of Therapy, FAGE,
Samarkand State Medical Institute

Alieva Nigora Rustamovna
Doctor of Medical Sciences, Head of the
Department of Hospital Pediatrics No. 1
with the basics of alternative medicine,
TashPMI

Ismailova Adolat Abduraximovna
doctor of Medical Sciences, Professor,
Head of the Laboratory of Fundamental
Immunology of the Institute of
Immunology of Human
Genomics of the Academy of Sciences
of the Republic of Uzbekistan

Kamalov Zaynitdin Sayfutdinovich
doctor of Medical Sciences, Professor,
Head of the Laboratory of
Immunogenetics of the Institute of
Immunology and Human Genomics
of the Academy of Sciences of the
Republic of Uzbekistan

Kayumov Ulugbek Karimovich
Doctor of Medical Sciences, Professor,
Head of the Department of Internal
Diseases and Telemedicine of the Center
for the development of professional
qualifications
of medical workers

Khusinova Shoira Akbarovna
PhD, Associate Professor, Head of the
Department of General Practice,
Family Medicine FAGE of the
Samarkand State Medical Institute

Shodikulova Gulandom Zikriyaeвна
Doctor of Medical Sciences, professor,
head of the Department of Internal
Diseases N 3 of Samarkand state medical
institute (Samarkand)
<https://orcid.org/0000-0003-2679-1296>

Халиков Каххор Мирзаевич
кандидат медицинских наук, доцент
заведующий кафедрой биологической
химии Самаркандского
государственного медицинского
университета

Аннаев Музаффар
Ассистент кафедры внутренних
болезней и кардиологии №2
Самаркандского государственного
медицинского университета
(технический секретарь)

Тулабаева Гавхар Миракбаровна
Заведующая кафедрой кардиологии,
Центр развития профессиональной
квалификации медицинских
работников, д.м.н., профессор

**Абдумаджидов Хамидулла
Амануллаевич**
Бухарский государственный
медицинский институт имени Абу
Али ибн Сино. Кафедра «Хирургические
болезни и реанимация». Доктор
медицинских наук, профессор.

Саидов Максуд Арифович
к.м.н., директор Самаркандского
областного отделения
Республиканского специализированного
научно-практического медицинского
центра кардиологии (г. Самарканд)

Насирова Зарина Акбаровна
PhD, ассистент кафедры внутренних
болезней №2 Самаркандского
Государственного Медицинского
университета (ответственный
секретарь)

Xalikov Qaxxor Mirzayevich
Tibbiyot fanlari nomzodi, dotsent
Samarqand davlat tibbiyot universiteti
Biologik kimyo kafedrasini mudiri

Annayev Muzaffar G'iyos o'g'li
Samarqand davlat tibbiyot universiteti 2-son
ichki kasalliklar va kardiologiya kafedrasini
assistenti (texnik kotib)

Tulabayeva Gavxar Mirakbarovna
kardiologiya kafedrasini mudiri, tibbiyot
xodimlarining kasbiy malakasini rivojlantirish
markazi, tibbiyot fanlari doktori, professor

Abdumadjidov Xamidulla Amanullayevich
«Abu Ali ibn Sino nomidagi Buxoro davlat
tibbiyot oliygohi» Xirurgiya kasalliklari va
reanimatsiya kafedrasini professori, tibbiyot
fanlari doktori.

Saidov Maqsud Arifovich
tibbiyot fanlari nomzodi,
Respublika ixtisoslashgan kardialogiya
ilmiy amaliy tibbiyot markazi Samarqand
viloyat mintaqaviy filiali direktori
(Samarqand)

Nasirova Zarina Akbarovna
Samarqand davlat tibbiyot instituti
2-sonli ichki kasalliklar kafedrasini
assistenti, PhD (mas'ul kotib)

Khalikov Kakhor Mirzayevich
Candidate of Medical Sciences,
Associate Professor, Head of the Department
of Biological Chemistry, Samarkand State
Medical University

Annaev Muzaffar
Assistant of the Department of Internal
Diseases and Cardiology No. 2 of the
Samarkand State Medical University
(technical secretary)

Tulabayeva Gavxar Mirakbarovna
Head of the Department of Cardiology,
Development Center professional
qualification of medical workers,
MD, professor

**Abdumadjidov Khamidulla
Amanullayevich**
“Bukhara state medical institute named
after Abu Ali ibn Sino”. DSc, professor.

Saidov Maksud Arifovich
Candidate of Medical Sciences, Director
of the Samarkand Regional Department of
the Republican Specialized Scientific and
Practical Medical Center of Cardiology
(Samarkand)

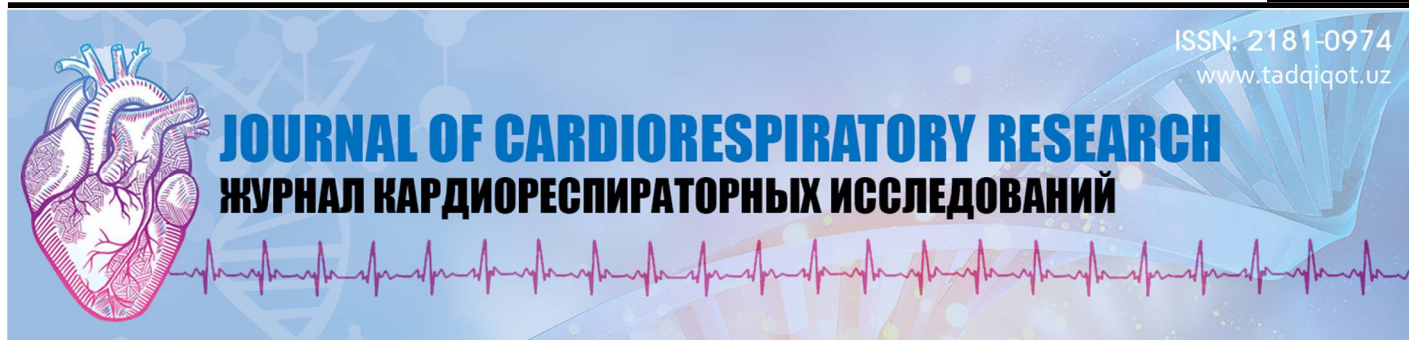Nasyrova Zarina Akbarovna
PhD, Assistant of the Department of Internal
Diseases No. 2 of the Samarkand State
Medical University (Executive Secretary)

ОБЗОРНЫЕ СТАТЬИ/ REVIEW ARTICLES /ABIYOTLAR SHARHI

1.	Аляви А.Л., Аляви Б.А., Абдуллаев А.А., Узокров Ж.К., Муминов Ш.К, Исхаков Ш.А., Вирхов И.П., Аширбоев Ш.П. Искусственный интеллект и его роль в улучшении диагностики кардиологических состояний Alyavi A. L., Alavi B. A., Abdullaev A. Kh., Uzokov J. K., Muminov Sh. K., Iskhakov Sh. A., Virkhov I. P., Ashirbaev Sh. P. Artificial intelligence and its role in improving the diagnosis of cardiological conditions Alyavi A. L., Alavi B. A., Abdullaev A. Kh., Uzokov J. K., Muminov Sh. K., Iskhakov Sh. A., Virkhov I. P., Ashirbaev Sh. P. Sun'iy intellekt va uning yurak kasalliklari diagnostikasini takomillashtirishdagi roli.....	11
2.	Абдумаджидов А.Х. Современное состояние эхинококкоза сердца Abdumadzhidov A.Kh. Modern status of heart echinococcosis Abdumadjidov A.X. Yurak exinokokkozining zamaniy statusi.....	18
3.	Абдумаджидов А.Х. Этиопатогенез формирования капсульных дефектов при хроническом ревматизме сердца. Современные проблемы диагностики Abdumadzhidov A.Kh. Etiopathogenesis of the formation of capsule defects in chronic heart rheumatism. Modern problems of diagnostics Abdumadjidov A.X. Etiopathogenesis of the formation of capsule defects in chronic heart rheumatism. Modern problems of diagnostics.....	26
4.	Адылова Ф.Т., Тригулова Р. Х., Давронов Р. Р. Модели искусственного интеллекта для прогнозирования сердечно-сосудистых заболеваний у людей с сахарным диабетом 2 типа: аналитический обзор Adilova F. T., Trigulova R. K., Davronov R. R., Artificial intelligence models for predicting cardiovascular diseases in people with type 2 diabetes mellitus: analytical review Adilova F. T., Trigulova R. K., Davronov R. R., 2-tur qandli diabet bilan og'rigan bemorlarda yurak-qon tomir kasalliklarini bashorat qilish uchun sun'iy intellekt modellari: tahliliy sharhi.....	33
5.	Муллабаева Г.У., Шодиметова Ш., Эргашев Ж.Я. Сердечная недостаточность у больных с сахарным диабетом Mullabaeva G.U., Shodimetova Sh., Ergashev Zh.Ya. Heart failure in patients with diabetes mellitus Mullabaeva G.U., Shodimetova Sh., Ergashev J.Ya. Qandli diabet bilan og'rigan bemorlarda yurak yetishmovchiligi.....	41
6.	Туйчиева С. К., Ташкенбаева Э. Н. Патогенетическая роль интерлейкина-6 и ФНО-α в развитии артериальной гипертензии у женщин с метаболическим синдромом Tuychieva S. K., Tashkenbaeva E. N. Pathogenetic role of interleukin-6 and TNF- α in the development of arterial hypertension in women with metabolic syndrome Tuychieva S. K., Tashkenbaeva E. N. Metabolik sindromi bo'lgan ayollarda arterial gipertenziya rivojlanishida interleykin-6 va TNF- α ning patogenetik roli.....	49
7.	Кенжаев С.Р., Латипов Ф.Ф. Убайдуллаева Ш.М. Причины синкопального синдрома и роль парадоксальной эмболии в возникновении синкопальных случаев у больных с врожденными пороками сердца Kenjaev S.R., Latipov F.F. Ubaydullaeva Sh.M. Causes of obincopal syndrome and the role of paradoxical embolism in the occupation of syncopal cases in patients with congenital heart devices Kenjaev S.R., Latipov F.F. Ubaydullayeva Sh.M. Sinkope sindromining rivojlanish sabablari va yurak tug'ma nuqsонlari bo'lgan bemorlarda sinkopal holatlarning yuzaga kelishida paradoksal emboliyalarning o'rni.....	54
8.	Тураев Х.Н., Зиядуллаев Ш.Х, Исмаилов Ж.А. Анализ антиромботической терапии мерцательной аритмии в международных и национальных реестрах Turaev H. N., Ziyadullaev Sh. X., Ismoilov J. A. Analyses of antithrombotic therapy for atrial fibrillation in international and national registries Turaev H. N., Ziyadullaev Sh. X., Ismoilov J. A. Analyses of antithrombotic therapy for atrial fibrillation in international and national registries.....	60

ОРИГИНАЛЬНЫЕ СТАТЬИ/ORIGINAL MAQOLALAR/ ORIGINAL ARTICLES

9. **Э.А. Абдуганиева, Ш.М. Ахмедов, Ю.Э.Фаттахова, Д.М. Халилова,**
Воздействие гомоцистеина на факторы коагуляции при хронической обструктивной болезни легких
E.A. Abduganieva, Sh.M.Akhmedov, Y.E. Fattahova, D.M. Halilova
Impact of homocysteine on coagulation factors in chronic obstructive pulmonary disease
E.A.Abduganiyeva, Sh.M.Axmedov, Y.E. Fattaxova, D.M. Xalilova
Gomosissteinning surunkal obstruktiv o'pka kasalliklaridagi koagulyatsiya omillariga ta'siri..... 64
10. **Ш.А. Амирова, С.Х.Ярмухамедова**
Изучение показателей диастолической дисфункции правого желудочка у больных с гипертонической болезнью
Sh.A. Amirova, S.Kh.Yarmukhamedova
Determination of indicators of diastolic dysfunction of the right ventricle in patients with hypertension
Sh.A. Amirova, S.X.Yarmuxamedova
Gipertoniya kasalligida o'ng qorincha diastolic disfunktsia belgilarini aniqlash..... 69
11. **А.И. Ахмедов, О.А. Ким, С.Э. Эшмуратов**
Нарушение ритма сердца у больных ревматоидным артритом
A.I. Akhmedov, O.A. Kim, S.E. Eshmuratov
Heart rhythm disturbances in patients with rheumatoid arthritis
A.I. Ahmedov, O.A. Kim, S.E. Eshmuratov
Rematoid artritli bemorlarda yurak ritmining buzilishi..... 73
12. **Мамаризаев И. К.**
Особенности влияния дисбиоза в развитие пищевой аллергии у детей
Mamarizaev Ibrokhim Komilzhonovich
Features of the influence of dysbiosis in the development of food allergy in children
Mamarizayev Ibroxim Komiljonovich
Bolalarda oziq-ovqat allergiyasi rivojlanishida disbioz ta'sirining o'ziga xos xususiyatlari..... 76
13. **Махматмурадова Н.Н.**
Дифференциальная диагностика неспецифической интерстициальной пневмонии
Makhmatmuradova N.N.
Differential diagnostics of nonspecific interstitial pneumonia
Maxmatmurodova N.N.
Nonspesifik interstitsial pnevmoniyaning differentsial diagnostikasi..... 80
14. **Ризаев Ж.А., Хусайнбоев Ш.Д.**
Оценка сердечно-сосудистой функции у байдарочников и каноев
Rizaev J. A., Xusainboev Sh.D.
Assessment of cardiovascular function in kayakers and canoeists
Rizaev J. A., Xusainboev Sh.D.
Baydarka va kanoeda eshkak eshuvchilarda yurak qon-tomir tiziminining faoliyatini baholash..... 83
15. **Рустамова Г.Р., Кудратова З. Э.**
Анализ акушерского анамнеза у матерей больных с хроническим тонзиллитом ассоциированных ЦМВИ и с вирусом Эпштейна Барра
Rustamova G.R., Kudratova Z.E.
Analysis obstetric anamnesis in mothers of patients with chronic tonsillitis associated with TSMVI and Epstein Barr virus
Rustamova G.R., Qudratova Z.E.
CMVI va Epstein Barr virusi bilan og'rikan surunkali tonzilliti bor bemorlarning onalarida akusherlik anamnezida tahlil qilish..... 88
16. **Хасанжанова Ф.О., Абдушукурова К.Р.**
Оценка структур и взаимосвязь факторов риска, предрасполагающих к инфаркту миокарда у лиц молодого возраста
Khasanjanova F.O., Abdushukurova K.R.
Assessment of the structures and interrelation of risk factors predisposing to myocardial infarction in young people
Xasanjanova F. O., Abdushukurova K. R
Yosh odamlarda miokard infarktiga moyil bo'lgan xavf omillarining tuzilishi va o'zaro bog'liqligini baholash..... 91
17. **О.А. Шиченко, Г.З. Шодикюлова**
Клинико-эпидемиологические особенности пациентов с неспецифической интерстициальной пневмонией
O.A. Shichenko, G.Z. Shodikulova
Clinical and epidemiological features of patients with nonspecific interstitial pneumonia
O.A. Shichenko, G.Z. Shodiqulova
Nonspesifik interstitsial pnevmoniya bilan og'rikan bemorlarning klinik va epidemiologik xususiyatlari..... 95



ISSN: 2181-0974

www.tadqiqot.uz

ADABIYOTLAR TAHLILI | REVIEW ARTICLES | ОБЗОРНЫЕ СТАТЬИ

Аляви Анис Лютфуллаевич

руководитель лаборатории
ГУ «Республиканский
специализированный
научно-практический медицинский
центр терапии и медицинской реабилитации»,
заведующий кафедрой
Ташкентского педиатрического
медицинского института,
д.м.н., Академик
Ташкент, Узбекистан

Аляви Бахромхон Анисханович

директор ГУ «Республиканский
специализированный
научно-практический медицинский
центр терапии и медицинской реабилитации»,
заведующий кафедрой
Ташкентского педиатрического
медицинского института,
д.м.н., профессор
Ташкент, Узбекистан

Абдуллаев Акбар Хатамович

руководитель лаборатории
ГУ «Республиканский специализированный
научно-практический медицинский
центр терапии и медицинской реабилитации»,
доцент Ташкентского педиатрического
медицинского института, д.м.н.,
Ташкент, Узбекистан

Узоков Жамол Камилович

Старший научный сотрудник
ГУ «Республиканский
специализированный
научно-практический медицинский центр
терапии и медицинской реабилитации»,
Ташкент, Узбекистан

Муминов Шовкат Каирович,

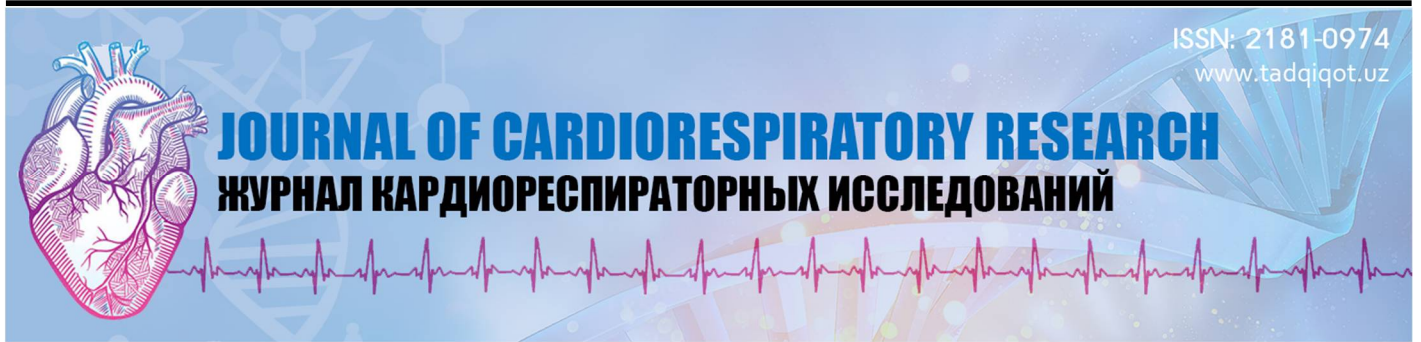Ведущий научный сотрудник
ГУ «Республиканский
специализированный
научно-практический медицинский центр
терапии и медицинской реабилитации»
Ташкент, Узбекистан

Исхаков Шерзод Алишерович,

младший научный сотрудник
ГУ «Республиканский
специализированный
научно-практический медицинский центр
терапии и медицинской реабилитации»
Ташкент, Узбекистан


Вирхов Игор Петрович,

младший научный сотрудник
ГУ «Республиканский
специализированный
научно-практический медицинский центр
терапии и медицинской реабилитации»

ISSN: 2181-0974
www.tadqiqot.uz

JOURNAL OF CARDIORESPIRATORY RESEARCH

ЖУРНАЛ КАРДИОРЕСПИРАТОРНЫХ ИССЛЕДОВАНИЙ

Х. А. АбдумаджидовБухарский государственный медицинский
институт имени Абу Али ибн Сино
Бухара, Узбекистан**СОВРЕМЕННОЕ СОСТОЯНИЕ ЭХИНОКОККОЗА СЕРДЦА****For citation:** Kh. A. Abdumadjidov. Modern status of heart echinococcosis. Journal of cardiorespiratory research. 2024, vol 5, issue 2, pp.18-25

<http://dx.doi.org/10.26739/2181-0974/2024/1/2>
АННОТАЦИЯ

В данной статье литературного обзора, посвященной проблеме эхинококкоза сердца, с критической точки зрения изложены данные эпидемиологии, методы диагностики и хирургического лечения. Приведены данные разных авторов относительно причин летальных исходов после операции и причин рецидива заболевания. В конце приведены дискуссионные вопросы диагностики и хирургического лечения.

Ключевые слова: эхинококкоз сердца, искусственное кровообращение, хирургическое лечение

Kh. A. Abdumadjidov.Bukhara State medical institute named
after Abu Ali ibn Sino.
Bukhara, Uzbekistan**MODERN STATUS OF HEART ECHINOCOCCOSIS****ANNOTATION**

This article of the literary review devoted to the problem of echinococcosis of the heart presents epidemiology data, methods of diagnosis and surgical treatment from a critical point of view. The data of different authors concerning the causes of deaths after surgery and the causes of recurrence of the disease are presented. At the end, there are debatable issues of diagnosis and surgical treatment.

Key words: cardiac echinococcosis, cardiopulmonary bypass, surgical treatment

X. A. Abdumadjidov.Abu Ali ibn Sino nomidagi
Buxoro davlat tibbiyot instituti
Buxoro, O'zbekiston**YURAK EXINOKOKKOZINING ZAMANIY STATUSI****ANNOTATSIYA**

Yurakning echinokokkozi muammosiga bag'ishlangan ushbu adabiy sharhda epidemiologiya ma'lumotlari, diagnostika va jarrohlik davolash usullari tanqidiy nuqta nazardan keltirilgan. Jarrohlikdan keyin o'lim sabablari va kasallikning qaytalanish sabablari bo'yicha turli mualliflarning ma'lumotlari keltirilgan. Oxir-oqibat, diagnostika va jarrohlik davolashning bahsli masalalari mavjud.

Kalit so'zlar: yurak exinokokkoz, suniy qon qonaylanish, jarrohlik davolash.

Echinococcosis of the heart is a severe zoonoanthropotic disease, which is characterized by a long chronic course, severe organ and systemic pathology, leading to disability and often to the death of the patient. From the moment of infection to the establishment of a diagnosis, there is a latent period lasting from 5 to 20 years. [14-22;51-55].

Echinococcosis of the heart continues to be a serious social and medical problem in many countries of the world, especially in epidemiologically disadvantaged regions [6-8;10-12;31-39].

The Central Asian Republics are one of the regions where the incidence rate reaches high figures, amounting to approximately 9 people per 100,000 population. Up to 1500 newly diagnosed patients with echinococcosis of one or another localization are operated annually

in Uzbekistan [1,2], while the especially high incidence of echinococcosis among people of the youngest, most able-bodied age turns into one of the important problems. It is necessary to note the obvious fact that there has been kova tendency to increase the number of patients in the developed countries of Europe and the USA. This, apparently, is due to an increase in the number of emigrants suffering from echinococcal disease.

[6-10;31-39]. For example, in the United States, about 100 new cases of echinococcosis are registered annually. In Russia, 800 initially diagnosed patients are registered annually; moreover, there has been a clear upward trend in the incidence [2,5]. Therefore, it is not surprising that, despite certain successes in the medical and surgical treatment of echinococcosis, it still remains a serious medical and social problem [1

2 -1 6 ; 31-39]. It is well known that echinococcosis most often affects the liver and lungs, which are considered to be the main target organs [22-23 ; 44-48]. However, in recent years, thanks to the capabilities of computed tomography and echocardiography (EchoCG), cases of identifying patients with rare localizations of echinococcal cysts, which include cardiac echinococcosis, have become more frequent.

According to the literature, the frequency of heart damage by echinococcosis is from 0.5 to 3 % among all echinococcosis [3-6 ; 11-14 ; 32-37]. Human echinococcal disease still remains an urgent problem of medical parasitology and surgery, especially in endemic areas of the Mediterranean coast, Africa, South America, Australia, New Zealand and, especially, Central Asia [8-10; 14-16; 37-39]. The attention of researchers, especially surgeons, was paid mainly to the

diagnosis and surgical treatment of patients with echinococcosis of the liver and lungs as the organs most often affected by the parasite [22-25;51-56;58-60]. Indeed, most often (50-75%) the liver is damaged, which is the first "filter" for portal blood and, consequently, for echinococcus embryos located in it [12-16;41-47]. The development of parasitic cysts in more than one organ is usually called "combined" forms of echinococcosis. With the introduction of modern radiation research methods into clinical practice, it has become possible to more often detect patients with cardiac echinococcosis [14-19;32-38]. As you know, the causative agent of parasitic damage to the heart is the larval stage of the helminth belonging to the species Echinococcus granulosus. The life cycle of echinococcus occurs with a change of two hosts (Figure 1.1).

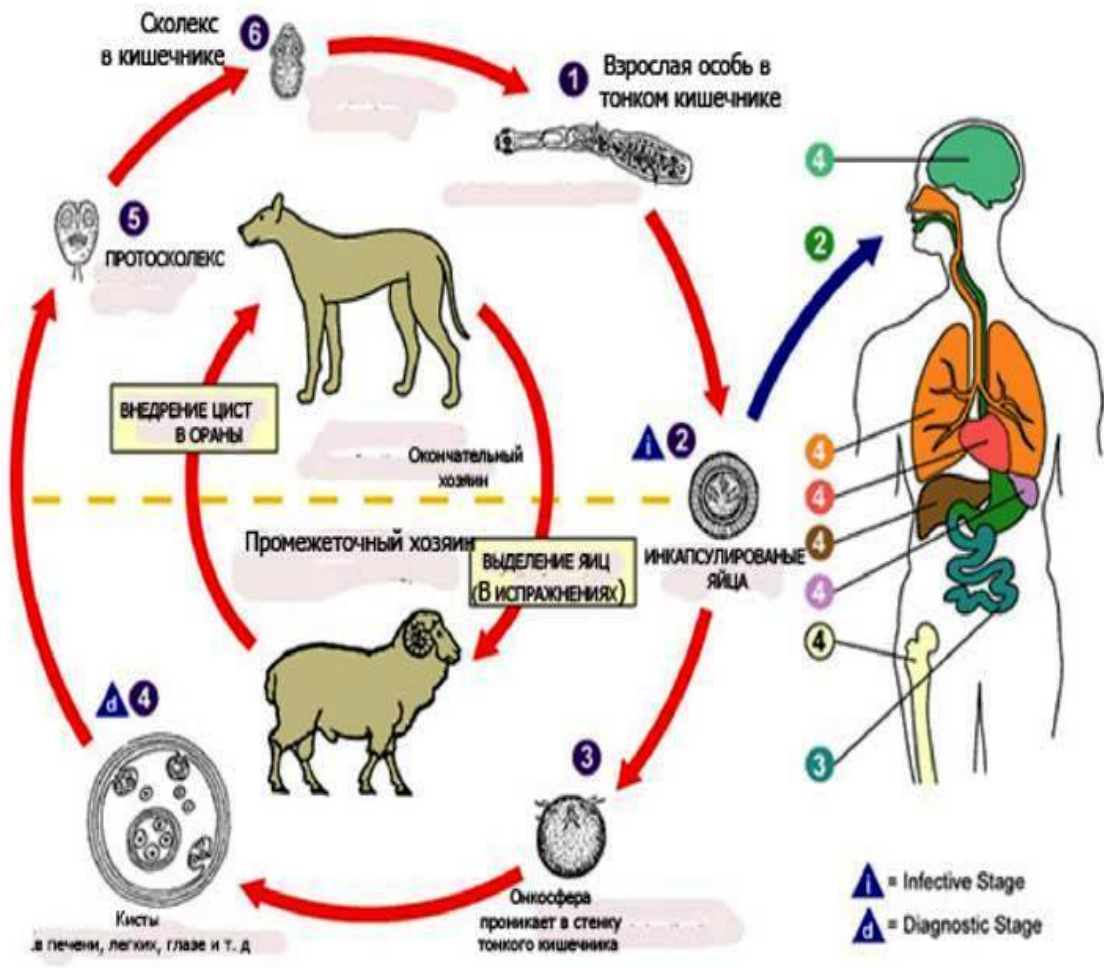


Fig.1.1. Scheme of the life cycle of echinococcus

The definitive (final) hosts, in whose body the sexually mature stage of echinococcus parasitizes, are: domestic dog, wolf, jackal, fox, lynx and other carnivores. Intermediate hosts in which the larval (bubbly) stage of echinococcus develops are: sheep, cattle, horse, buffalo, camel, pig, goat, deer, monkey and some rodents, as well as humans. Dogs become infected by eating the entrails of animals with echinococcal cysts. The germinal elements contained in the cyst (protoscoleces and acephalocysts) attach to the wall of the dog's colon and grow into adults. Mature segments containing 400-800 oncospheres come off the trousers; infected dog feces pollute the grass, the ground; eggs enter the intestines of sheep, pigs, camels or humans, on the hair of dogs. A person can become infected by petting a dog or eating contaminated vegetables. The role of meat products in the growth of morbidity should be recognized as minimal, since both humans and farm animals are intermediate hosts, and heat treatment of meat almost always leads to the death of the parasite. The eggs of the parasite (oncosphere) are covered with a membrane that dissolves under the action of gastric juice.

The released parasites pierce the intestinal mucosa and enter the liver through the portal vein system, where they develop into a mature cyst. Most parasites linger in the liver, so 54 to 84% of cysts form in the liver. Separate eggs pass through the liver and, bypassing the heart, are retained in the pulmonary capillary bed, which leads to the formation of pulmonary cysts (15-20%). When the parasite enters the systemic circulation, cysts are formed in the spleen, brain and heart. A maternal cyst develops from the germinal echinococcus, which is a bubble filled with fluid. The wall of the cyst consists of two membranes: the outer cuticular (chitinous) and the inner germinal (embryonic). From the outside, the cyst is surrounded by a dense connective tissue fibrous capsule, which is formed as a result of protective reactions of the intermediate host in response to the metabolic products of the parasite and performs a kind of skeletal and protective functions, protecting the parasite from mechanical damage and from the host's immune attack. The larval stage of echinococcus is a fluid-filled bubble that can reach sizes from a millet grain to the head of a newborn baby or more. The

wall of the bladder consists of an outer, cuticular membrane and an inner, germinal (germinal) layer. The bladder cavity is filled with liquid, in which scolexes, daughter and granddaughter vesicles often float freely. The chitinous membrane has a layered structure. With the growth of the bubble, the thickness of the chitinous shell also increases. The number of scolexes in one bladder can be from several tens to hundreds. Echinococcal fluid is transparent, colorless, its specific gravity is 1007-1015, the reaction is neutral or slightly acidic. The liquid contains amino acids, proteins, proteolytic and glycolytic enzymes, sodium chloride, calcium, acids, lecithin, cholesterol, ammonium salts. Echinococcal fluid has toxic and allergic properties. The sexually mature form of echinococcus is a small cestode 2.7-5.4 mm long, consists of 3-4 segments. The scolex is armed with a double crown of 30-40 hooks and has 4 muscular suckers. The egg is oval, has a shell. Each egg contains a six-hooked embryo - an oncosphere. The main route of penetration of the oncosphere into the human body is the gastrointestinal tract. Once in the digestive tract of the host, the oncosphere is released from its shell and penetrates into the thickness of the mucous membrane of the stomach or intestines, from where it enters either venous or lymphatic vessels. Most often, it enters the portal vein through the superior mesenteric vein and can settle in the liver. Part of the embryos that have passed the hepatic barrier through the inferior vena cava, the right atrium, the right ventricle and the pulmonary circulation enter the lungs, where the oncospheres can linger in the pulmonary capillaries. It can be assumed that some of the oncospheres penetrate the arteriovenous anastomoses of the liver and lungs and, having passed into the left parts of the heart and aorta, enter the systemic circulation. Single oncospheres can be introduced into any organ and any tissue, where they gradually turn into echinococcal blisters [2-5;10-18]. Moreover, there are indications that infection with echinococcus can occur not only through the digestive tract, but also through the aerogenic route, through the wound surface, the conjunctiva of the eyes and salivary ducts. As the cysts grow, their constant pressure on the surrounding tissues and organs causes functional disorders and pathological changes in the body of the intermediate host. Gradually, intoxication also increases due to toxoalbumins, located in the echinococcal fluid and diffusing through the lymphatic ducts into the pericystic space.

The main reasons that lead to infection with this parasite are: contact with infected animals (pigs, sheep, cows, dogs, horses and other animals); eating contaminated animal meat; contact with contaminated soil, animal hair (parasite eggs are excreted with feces); making clothes from the fur of infected animals; collection of berries or herbs infected with parasite eggs; drinking water from contaminated reservoirs; eating unwashed fruits and vegetables.

Secondary echinococcosis develops without a change of host, i.e. self-infection occurs. Secondary echinococcosis is observed much less frequently than primary. The spread of the parasite in the host organism occurs in the following ways: 1) hematogenous; 2) along the serous membranes; 3) through the mucous membrane; 4) lymphogenous. Four types of echinococcosis are distinguished depending on the distribution routes. The first - implantation - recurrence of echinococcus after implantation of bladder elements during surgery or puncture. The second - after the breakthrough of the cyst into the abdominal or pleural cavity, followed by seeding. The third - metastatic - when elements of an echinococcal cyst spread in the form of emboli. It is more often observed with perforation of the echinococcal bladder of the heart. The fourth is secondary echinococcal cysts that form on the mucous membranes.

The death of the echinococcal bladder is one of the important points in the clinic of the disease. At the same time, the liquid becomes cloudy, absorbed, and part of it turns into a putty-like mass, the germinal layer is destroyed, the shells are impregnated with lime salts. A small cyst may disappear completely, leaving only a scar in its place. The death of the echinococcal parasite can be caused by the lack of proper conditions for its development, hemorrhage into the cyst or suppuration, injury and perforation of the cyst, physiological aging of the cyst.

High incidence of echinococcosis in regions with predominant development animal husbandry is associated with a low level of socio-economic development and sanitary culture of the population. In

economically developed countries, the increase in the incidence occurs mainly due to immigrants and the development of tourism. In these regions, as well as in non-endemic foci, doctors are often not ready for timely diagnosis and adequate treatment of patients with echinococcosis.

In the last two decades, due to the introduction of the most modern highly informative research methods into clinical practice, cases of identifying patients with rare localizations of echinococcal cysts, in particular, cardiac echinococcosis, have become more frequent [11-21; 42-51]. According to the literature, echinococcosis of rare localizations (bones, brain, muscles) is 12.2% of cases. With these, rare, localizations of echinococcosis, the oncosphere of the parasite reaches certain organs through the systemic circulation.

According to the average data [17-19; 26-29; 52-59], among all examined or operated patients with echinococcosis of various localizations, 0.2 - 1.3% of cases had concomitant damage to the heart or pericardium.

Despite the relative rarity of cardiac echinococcosis, interest in this localization of parasitic cysts has rightly increased in recent years, since the possibility of radical surgical treatment of these patients under cardiopulmonary bypass has appeared.

Echinococcosis of the heart, according to various authors, accounts for 0.5-3% of all echinococcosis diseases [7-12;30-37;41-48]. Mostly people of the most able-bodied age, that is, in the range from 20 to 40 years, get sick; patients in this age range account for 70-75% of all patients with heart echinococcosis. At the same time, if the localization of parasitic cysts in the liver and lungs is more often observed in women, then heart echinococcosis more often affects men. Many authors attribute this ratio to the fact that the incidence of echinococcosis is influenced by social aspects, the nature of the profession, migration processes and contact with animals [9-14;20-23;52-57]. The combined forms of echinococcosis indicate the possibility of a one-time or prolonged massive invasion by oncospheres. As a rule, there are cysts of the heart with a predominant lesion of the ventricles. In this case, the left ventricle is affected 2-3 times more often than the right one [24-29; 31-39; 43-48], accounting for 55-15% of all cases of cardiac echinococcosis. The atria are affected equally often - in 5-7% of cases [41,48]. Isolated lesions of the interventricular septum are extremely rare [9-14; 19-25]. In most cases, left ventricular cysts are located subepicardially, right ventricular cysts - subendocardially. This explains the breakthrough of LV cysts into the pericardial cavity, and the cysts of the pancreas - into the cavity of the heart, which is one of the fatal complications of heart echinococcosis - 2/3 of the dead die from rupture of the cyst. Intracardial localization of cysts directly in the chambers of the heart is rare [10-19; 31-39]. Echinococcal cysts of the heart are more common, in 82.2% [32-41; 8% of cases - multiple. The number of cysts can be in the tens and even hundreds, and the more cysts, the smaller their size. In these cases, the heart muscle seems to be stuffed with echinococcal cysts [34,39]. Pericardial damage is more often combined either with echinococcosis of the lungs, or with damage to the atria and ventricles. According to the literature, an isolated pericardial lesion is extremely rare. Echinococcal cysts grow slowly, increasing by an average of 1-3 cm per year, so they remain asymptomatic and undiagnosed for a long time. According to the literature, echinococcal cysts located in the ventricles of the heart die early, rarely reaching significant sizes. These authors associate this fact with continuous contraction of the myocardium. Therefore, this mechanism leads to the fact that the intramurally located echinococcal cyst does not have a rounded shape, which is usual for target organs, but is deformed, with several diverticulum-like protrusions, formation. Parasitization of an echinococcal cyst in the tissues of the heart always leads to an increase in this organ. The heart affected by echinococcosis increases in size, can push back and squeeze the mediastinal organs and even the lungs. Under the influence of the parasite in the process of its growth, changes in tissues occur and clinical signs of the disease appear. Growing larvocyts put pressure on myocardial muscle fibrils - their ischemia develops, which can mimic coronary heart disease [8-12;23-29]. When the cyst of the parasite is localized in the interventricular septum, the conduction of the bundle of His is disturbed. Sclerosis and dystrophy of his legs are also possible, that is, there are anatomical

prerequisites for the development of complete atrioventricular heart block with or without Morgagni - Edems -Stokes attacks

[14-17;20-33]. Growing larvocysts , protruding into the cavity of the heart, can mechanically disrupt the outflow of blood. In the presence of large parasites, the flow of blood into the atrium from the caval or pulmonary veins is hindered, and the covering of the atrioventricular openings is not excluded , or vice versa, creating a situation that contributes to the occurrence of tricuspid valve insufficiency [10-13; 24-30] . Larvocysts , especially those that perforate into the left half of the heart, lead to embolism of the coronary vessels, primarily the left coronary artery. Perforation is observed in the presence of large larvocysts , when they protrude significantly into the lumen of the ventricles, where they usually open. Due to the fact that cardiac larvocysts almost always contain child bladders, embolisms often occur during the rupture of the maternal bladder, blockage of the pulmonary artery [45;52] or its branches by echinococcal bladders and their membranes may occur. In addition to mechanical blockage , which is caused by daughter blisters and their membranes, the intake of infected, toxic, allergenic echinococcal fluid with the development of an anaphylactic reaction is also essential [31;37] . Intracardiac localization of cysts directly in the chambers of the heart is rare [9;17] . Localization of a cyst in one or another part of the heart determines the clinic of the disease, predetermines the prognosis, the nature of the operation and the outcome of the disease. As you know, the ventricles of the heart have different wall thicknesses and different systolic pressures in the chambers; in addition, a certain distinct pattern of localization of intramural cysts was revealed - in the pancreas they “lie” subendocardially , and in the left ventricle - subepicardially . This explains the more frequent breakthrough of left ventricular cysts into the pericardial cavity (EkleT . 2012; HaggiuA . 2012), and right ventricular cysts - directly into the heart cavity. Cyst perforation is observed with a frequency of up to 30% of cases, almost 2/3 of the dead die from cyst rupture (ZiadiA . 2014; JinP . 2012). The clinical picture of cardiac echinococcosis is nonspecific, diverse. There are practically no pathognomonic subjective clinical signs of echinococcosis. Most often, patients note pain in the heart, shortness of breath, cough , palpitations, fever; paroxysmal tachycardia with extrasystole may occur. The breakthrough of the cyst dramatically changes the clinical picture of the disease, which entirely depends on the direction of the breakthrough (cardiac tamponade, embolism of the vessels of the large or small circulation). A complication in the form of agglomeration or suppuration of the cyst causes an even greater variety of symptomatology [6-12; 31-34] . The clinical course of echinococcosis in some cases is asymptomatic . However, despite the advances in modern medicine, the diagnosis of cardiac echinococcosis is still a difficult task. In this regard, the analysis of the significance, role and capabilities of modern methods for diagnosing cardiac echinococcosis is of both scientific and practical interest . Clinical and laboratory methods for blood tests in cardiac echinococcosis provide an opportunity to obtain additional information. First of all, this refers to an increase in the number of eosinophils, which, according to various authors, occurs in 18-83% of cases. In this case, eosinophilia is a sign of a living parasite; with calcification or death of the cyst, this symptom is absent; after echinococcectomy eosinophilia completely disappears. Also, there may be an increase in ESR and blood leukocytosis [41-48;50-54] .

Electrocardiography - with echinococcosis of the heart, although it is not considered a reliable research method, it provides important information. According to [21-28;30-33] , ECG reveals nonspecific changes in ST segments, signs of incomplete and complete blockade, and ventricular hypertrophy.

X-ray method of research is an invaluable method for diagnosing combined echinococcosis of the heart and lungs. For this purpose, multi-axis fluoroscopy, radiography in frontal and lateral projections are used. Small cysts are detected using a layered X-ray examination - tomography. A characteristic radiological sign of echinococcosis of the heart is the determination of a rounded shape against the background of the heart, a formation of uniform intensity with clear even contours, areas of increased density - these signs are described in scientific papers. On X-ray kymograms, there is a transmission pulsation along the

contour of the formation. In most cases, an increase in the shadow of the heart with an unusual deformation of its contours is detected [26–29; 33–39] . The absence of pathognomonic clinical symptoms, the lack of expression of clinical signs and laboratory changes, and the inconsistency of serological reactions dictate the need for the use of instrumental diagnostic methods.

According to the classification developed by WHO experts, parasitic heart cysts are divided into 4 types. 1-type - simple cysts without internal architecture; type 2 - cysts with an internal matrix and daughter cysts; 3-type calcified parasite cysts; 4-type - festering cyst.

Computed tomography makes it possible to detect very subtle structural changes without resorting to invasive studies [10-17;33-39] . On computed tomography , parasitic cysts appear as rounded formations with clear, even contours. Calcification of the cyst greatly facilitates differentiation. Internal structures indicate the presence of daughter cysts. CT provides valuable information about the location, size, and involvement of the tissue surrounding the echinococcal cyst, however, according to [6;10] , it does not allow differentiating an injured or infected cyst from an abscess.

With combined forms of echinococcosis, complex radiation diagnostics using X-ray examination, ultrasound and CT can increase the information content of diagnosis up to 97%. At the same time, the data of such a complex of studies make it possible to plan the nature, sequence and stages of surgical intervention on the heart and other target organs [7-12;33-38].

Echocardiography is a non-invasive , reliable, sensitive and, therefore, affordable method for diagnosing cardiac echinococcosis [25-31;48-52] . So, transthoracic , even better. transesophageal , echocardiography allows you to accurately see a volumetric, round-shaped cavity formation with clear contours, determine its size, localization; thanks only to echocardiography, it is possible to differentiate a cyst from neoplasms, its connection with the intracavitary structures of the heart, determine the degree of mobility of the cyst and the density of its contents [10-19;52-60] . All of the above allows most clinicians to quite rightly consider echocardiography as the method of choice in the diagnosis of cardiac echinococcosis [22-27; 30-42] . Previously, it was believed that ventriculo-coronary angiography is justified if, with established cardiac echinococcosis, the ECG shows changes in the type of myocardial ischemia. However, today, given the modern possibilities of echocardiography, it is legalized [9-12;45-49] that there is no need to perform ventriculography in case of cardiac echinococcosis , because the latter itself carries an additional danger to the patient. During invasive examination methods, there is a risk of puncture of subendocardial located cysts.

The first successful operation for cardiac echinococcosis dates back to 1921 (P. Marten et al). In the CIS countries, the first successful echinococcectomy from the heart was performed by M.T. Kudrin in 1955 under local anesthesia. The priority of the first successful echinococcectomy from the interventricular septum belongs to [51;59] . The first operation of echinococcectomy from the heart with LV plasty under EC was performed by A.A. Kolesnikov in 1963. In our country, the first successful echinococcectomy from the heart under EC conditions was carried out by Professor D.S. Gulyamov in 1994.

According to [35-59;52-57], cardiac echinococcosis requires urgent surgical intervention. In recent years, approaches to the treatment of patients with echinococcosis have changed somewhat. Along with traditional operations, minimally invasive (percutaneous , thoraco- and laparoscopic) interventions have become possible, some authors have recognized the effectiveness and possibility of conservative treatment [31;39] . However, according to most authors, in case of heart echinococcosis, small, sparing interventions are not applicable, conservative treatment is impossible, the only method is surgical treatment [8;12] .

When analyzing the literature, it was revealed that every sixth patient dies from bleeding during surgical treatment, especially if the latter is not performed under EC conditions. Therefore, some authors, fearing the occurrence of a number of complications (bleeding, myocardial rupture, etc.), consider it expedient to perform EE from the heart under conditions of EC and CP [6]. We also consider it expedient and justified to perform EE under conditions of EC and CP on an

“immobilized” heart. As can be seen from the above, in the choice of intraoperative tactics, in relation to the use of EC, many unresolved issues remain to this day. The practical significance of the problem under consideration is determined by the particular difficulty of measures for the prevention of cardiac echinococcosis, the complexity of its early diagnosis, the need and the possibility of using only a surgical method of treatment. According to the literature, there was a distinct trend towards the location of the hydatids closer to the apex of the left ventricle, in the thickness of the myocardium. They consider the early death of the parasite to be an important feature of cardiac echinococcosis, which, apparently, is a consequence of the structure of the heart muscle and its constant contraction. Regarding the number of operations to remove hydatid cysts from the heart, it should be noted that the experience of a single group of authors, as a rule, is not great and usually does not exceed 5-7 observations [32] report five successful echinococcectomy from the heart; V.A. Ivanov et al., (1999) out of 5 patients examined by them with echinococcosis of the heart, only two

underwent surgical treatment; M.A. Aliyev et al. (1997) performed three successful echinococcectomy, 2 of them without the use of cardiopulmonary bypass. The largest number of echinococcectomy operations from the heart under cardiopulmonary bypass are [33-37;43-51], these teams of authors operated on more than 10 patients with various forms of localization of cardiac echinococcosis.

Treatment of cardiac echinococcosis is carried out according to all the rules of purulent-septic surgery, since ES refers to intracardiac infections (Shevchenko Yu.L.). According to the literature, surgical treatment is the method of choice for cardiac echinococcosis [6-8;10-12;14-16]. These operations required the development of new optimal surgical tactics, since the ideal echinococcectomy, which involves the complete removal of a cyst with a fibrous capsule, is unacceptable in heart surgery.

When choosing a surgical approach, a number of authors prefer operations on the "working" heart through the thoracotomy approach, especially in pericardial echinococcosis [2].

Table №1

Rate of in-hospital mortality and recurrence of cardiac echinococcosis

And the second	Number of patients	Number of operations	Lethality rate	Relapse rate
ThameurH (2001) Tunisia	45	45	5.5%	4.4%
ElhattaouiM . (2006) Morocco	7	7	28%	
Vakeli Murat (2007) China	15	15	6.6%	26.6%
Jerbi S (2007)	5	5	20%	
OrhanG . (2008) Turkey	25	25	4%	4%
KardarasF . (2010) Greece	10	6	thirty%	
Molavipour A (2010) Iran	eleven	eleven	18.1%	
Shevchenko Yu.L. (2016) Moscow	19	15		
RSNPMCH (2018) Tashkent	83	83	6.8%	2.7%

Operation on a “working” heart to remove an echinococcal cyst is associated with a number of complications, such as dissemination of the contents of the cyst, the possibility of accidentally taking nearby coronary vessels into the suture during the cardiac cycle, perforation of the cyst during treatment of the parasite bed, the risk of aeroembolism, and non-radical removal with a high risk of disease recurrence. As can be seen from Table No. 1.1 until 2000, no more than 30 observations of those examined and operated on for heart echinococcosis are described in the literature. After 2000, the detection of patients and the number of those operated on for heart echinococcosis increased significantly. This indicates, firstly, an improvement in the quality of diagnostic studies, and secondly, the emergence of the possibility of radical treatment of this category of patients.

1. Indications for surgery for cardiac echinococcosis are discussed, however, there is no doubt that the detection of a live echinococcal cyst is an absolute indication for surgery [2-5;12-16;30-38]. With respect to partially calcified cysts, some authors are inclined to the need for surgery. According to V.A. Ivanov et al. (1999) for cysts less than 5 cm in diameter that do not cause clinical manifestations, surgical treatment is not indicated. For echinococcectomy from the heart, the ideal approach, without a doubt, is a longitudinal, median sternotomy, which provides the surgeon with good access to all parts of the heart and convenience for connecting a heart-lung machine. (2007), the cyst extirpation operation had to be supplemented with complex reconstruction: ventricular septal plasty with autopericardium, annuloplasty tricuspid valve due to its insufficiency, as well as

implantation of the pacemaker due to complete AV blockade due to compression of the conduction pathways. Discussing the very technique of removing a cyst from the heart, SS Kabbani et al. intact cysts is the method of choice, because this method completely prevents the possibility of dissemination. Enucleation, the authors believe, can be performed without any consequences, especially if echinococcal cysts are located subepicardially, closer to the tops of the ventricles. However, in order to avoid rupture of the cyst, it is first recommended to puncture the cyst, then introduce agents that cause the death of larvae, and then remove the cyst wall and its contents. The issue of eliminating the residual cavity after echinococcectomy from the heart remains uncertain. So, Zh.K. Mitrev et al. (2005) after removal of the cyst, the bed of the parasite is eliminated by applying multi-row circular-corrugated sutures, starting from the bottom of the formed funnel-shaped defect in the thickness of the myocardium of the ventricles. Other authors [21-25;47-51], who have sufficient experience in the surgical treatment of cardiac echinococcosis, act in approximately the same way. The problem of the residual cavity after EE from the heart, especially with the so-called "large" cysts, is still debatable. Some authors fill the parasite cavity with a piece of autopericardium or move a strand of the greater omentum from the abdominal cavity into the cyst cavity [1-2.]. With “large” intramural LV cysts, after EE, a large cavity with thin walls remains and the risk of rupture and development of an aneurysm is very high. Aminov R.S. (2007) suggests omentocardiopexy to eliminate the residual cavity. To do this, through the incision in the diaphragm, a strand of the greater omentum on the vascular pedicle is

passed into the chest cavity and tamponated, fixed with sutures to the fibrous membrane of the heart cysts. The author points to improvements in coronary blood flow. In addition, according to the authors, it prevents the development of aneurysm in the area of echinococcectomy. In the literature, unfortunately, there is no single point of view regarding the tactics of surgical treatment of combined echinococcosis of the heart and other organs, in particular the liver and lungs. With combined echinococcosis of the heart and one of the other target organs, the main and decisive task is to determine the scope and sequence of the operation. Many authors believe that the first operation should be on an organ with a more severe lesion or if there is a threat of complications from one of the cysts on this organ. So, in many sources it is reported about the successive-staged removal of echinococcal cysts, first from the liver, after a short period of time - from the heart [2-5;17-23]. Also, SSKabbani et al. (2007) in 8 of their observations with extracardiac localization of cysts, the first stage of echinococcectomy was performed from the heart, after 3-6 months - from the liver or lungs. A small group of authors [1-2;10-17;30-34] in practice performed successful surgical interventions for combined simultaneous-sequential removal of echinococcal cysts from the heart and another target organ. According to Shevchenko Yu.V. (2016) the question of the sequence of echinococcectomy remains debatable, given the small number of publications regarding single-stage echinococcectomy from the heart and another target organ, this issue requires further study. Perhaps the sequence of stages of surgical intervention depends on the severity of the lesion and the patient's condition.

A method of simultaneous surgical treatment of echinococcosis of the heart and lungs is known in the literature (Travin N.O. 2007). The authors substantiate the simultaneity of the intervention in combined echinococcosis of the heart and lungs by the fact that echinococcosis cysts are located in the same anatomical cavity, i.e. chest cavity. This method does not allow surgical intervention in case of combined echinococcosis of the heart and abdominal organs, i.e. at an arrangement of an echinococcal cyst in different anatomical cavities.

However, R. Parvisietal. (2013) proposes to perform a simultaneous operation for combined echinococcosis of the heart and liver. At the same time, he used a subcostal approach to remove an echinococcal cyst from the liver and a longitudinal sternotomy to access the heart. The disadvantage of this method is the high morbidity of the subcostal approach, that is, almost all muscle groups of the anterior abdominal wall are intersected, the high incidence of postoperative hernias and deformities of the anterior abdominal wall.

Some authors [9;15] for preliminary sterilization of the cyst cavity before its removal use various solutions: 2% formalin, 0.5% silver nitrate, 30% sodium chloride solution, 1% iodine, 85-87% aqueous glycerol solution. Until recently, many surgeons have widely used 2% formalin to treat the fibrous cap. But its toxic effect on the liver of patients limited its use; moreover, there are reports of the preservation of the viability of scolexes in a 2% formalin solution when exposed for two hours. The most reliable and suitable for practical use were 30% sodium chloride solution and 80-100% glycerin solution. A solution of glycerol causes 100% death of parasites after 1-10 minutes and acts on protoscolexes and acephalocysts, responsible for the recurrence of the disease. Glycerin is active even at a significant dilution, which guarantees its greater reliability. These germicides are justified in the antiparasitic treatment of cysts during operations.

Despite the fact that historians of medicine attribute the first attempts at surgical treatment of parasitic cysts to Hippocrates, so far there is no consensus among experts on the choice of the optimal strategy for the medical treatment of cardiac echinococcosis. There are reports of positive results of conservative treatment with albendazole. Other authors limit the scope of non-surgical chemotherapy only to patients with unresectable options or who refuse surgery. Still others perform intervention on the heart after a course of chemotherapy, and also recommend that therapy be carried out after surgery [23-26;47]. The fourth consider the treatment with albendazole before surgery to be deadly and absolutely contraindicated due to the softening of the parasite wall during treatment and the multiply increasing risk of cyst rupture [3-6;36]. Finally, fifth note the low effectiveness of chemotherapy even after the removal of hydatids. We use

chemotherapy only in the postoperative period to prevent recurrence of the disease.

In the aspect of conservative therapy of cardiac echinococcosis, there is a significant difference from the treatment of other target organs. In particular, in the preoperative period, the use of antiparasitic drugs is not recommended [2-7;22-30], since the above therapy causes the death of the parasite and destruction of the cyst walls, which can lead to perforation of the cyst into the cavity of the pericardium or heart with all the ensuing consequences. In contrast, [23-28;30-38] indicate that anthelmintic drugs cause a decrease in the size and number of echinococcal cysts, but do not lead to complete recovery; the listed authors recommend antiparasitic treatment both before the operation and within 6 months after it. The same long-term anthelmintic therapy using albendazole or mebendazole (10-15 mg / kg / day for 3-5 courses of 28-30 days with a break between courses of 10 days) is recommended by R. Rein et al. (1996). The most serious attention should be paid to the implementation of a complex of anti-relapse measures, including repeated courses of drug-specific therapy in the postoperative period, in case of cardiac echinococcosis. A rational combination of surgical and medical measures to influence the disease will certainly improve the results of treatment of this complex category of patients.

Hospital mortality after surgical treatment of cardiac echinococcosis in the literature is not covered enough, because, in the vast majority of cases, we are talking about single operations. So, in the series [3-6;28-39] operational lethality was reduced to zero. At the same time, Yu.L. Shevchenko and his colleagues (2006) bitterly emphasize that out of 7 non-operated patients, 5 (71%) died in the coming years, and in the series of SS Kabbani et al., (2007) out of 19 operated 4 (21%) died in the next year after the intervention due to acute cerebrovascular accident (rupture of an echinococcal cyst of the brain) or multiple organ failure (cysts in the kidneys and liver). In most observations, we are talking about single operations. So, in 45 cases, according to T ha meur H. et al. (2001) lethality was observed in 5.5%, recurrence of the disease - 4.4%; according to Elhattaoui M., et al. (2006) lethality was observed in 28% of cases; according to Jerbi S. et al (2008) - in 20% of cases. Orhan G. et al. (2008) notes mortality and recurrence in 4% of cases.

The recurrence rate of isolated cardiac echinococcosis after various types of surgical treatment is 2-22% [18,33,58]. With combined damage to the heart and target organs, the frequency of relapses increases to 10-36%. Relapses are detected within 1 to 20 years after surgery. In accordance with the reasons that led to the recurrence, there are implantation, metastatic, residual and reinvasive echinococcal cysts. There is no doubt that the remaining viable elements of echinococcal cysts are the cause of most relapses. The reasons for the development of relapses are the ingress of parasitic fluid into the pericardial cavity during puncture of the cyst or during its rupture, drainage of the echinococcal cyst, technical errors during the operation, which led to the entry of elements of the removed cyst into the surgical field, independent migration of scolexes at some distance from the primary cyst. The sensitivity and resolution of modern research methods is not unlimited, and this leads to the fact that some of the small cysts remain undetected before and during surgery. These cysts cause recurrence. It cannot be ruled out that a significant part of relapses is the result of re-infection, since after the operation, patients return to their previous living conditions, and immunity is not developed after the disease. A number of authors note the absence of relapses in the follow-up period of 17-72 months [22;46]. In 20% of patients with echinococcosis who received conservative treatment, various complications were noted. The most frequently noted are increased pain in the area of cysts, allergic reactions, fever, increased cough, leukopenia, hypo - dysproteinemia, increased ESR. The occurrence of complications is associated with inflammation and damage to the parasite capsule, increased antigenic effects of the parasite on the body. With the development of complications, it is recommended to interrupt treatment, prescribe antibacterial, detoxification and desensitizing therapy, and after the patient's condition improves, continue taking anthelmintic drugs [41]. Table 1 below shows the percentage of lethality and recurrence according to the literature. The data of our study on postoperative mortality and disease recurrence correspond to the literature data.

Thus, summarizing the above brief review of the literature, it can be stated that the following issues of surgical treatment of cardiac echinococcosis remain definitively unresolved or debatable:

1. The optimal variant of the "conditions for ensuring" echinococectomy from the heart has not been determined.
2. The optimal options for surgical tactics in isolated and combined echinococcosis of the heart and target organs have not been determined;

3. The possibilities of simultaneous surgery for combined echinococcosis of the heart and target organs have not been determined;
4. The issues of elimination of the residual cavity after echinococectomy are not covered ;
5. Morphological bases of perforation of echinococcosis of the heart have not been studied.

References/Список литературы/Iqtiboslar

1. Abdurahimov 3.3., Gulmuradov TG, Aminov PC Diagnosis and surgical treatment of cardiopericardial echinococcosis. Central Asian Journal of Cardiovascular Surgery. 2008; 2 : с.8-12
2. Aminov PC Diagnostics and tactics of surgical treatment of cardio -pericardial echinococcosis. Bulletin of Avicenna. 2009;2:23-26.
3. Shevchenko Yu.L. Nazyrova F.G. Echinococcosis surgery . Moscow 2016.
4. Shevchenko Yu.L. Echinococcosis of the heart and lungs: strategy and tactics of treatment // Almanac of Clinical Medicine. 2007. - T. 16, -S. 216-218.
5. Shevchenko Yu.L. Features of clinical diagnosis and surgical treatment of echinococcosis of the heart and lungs // Vestn . National Medical and Surgical Center. N.I. Pirogov. 2007. - Vol. 2, No. 1, -S. 4-5.
6. Shevchenko Yu.L. Echinococcosis of the heart is a surgical problem // Bull . NTs SSH them. A . N . Bakuleva .- 2007. - T . 8, No. 3. - S. 24.
7. Bouassida I , Pricopi C , Mangiameli G , Arame A , Auliac JB , Gorbatai B , Riquet M , Le Pimpec Barthes F . Cardiac compression of hydatid origin. Rev Pneumol Clinic . May 17, 2018
8. Ben Khalfallah A , Ben Slima H . Cardiac hydatid cyst. Which imaging modality for an accurate diagnosis? Ann Cardiol Angeiol (Paris). Epub 2017 Mar 23.
9. Streliaeva AV , Sagieva AT , Abdiev FT , Sadykov RV , Sadykov VM , Gabchenko AK , Murtazaev ZI , Akhmedov IuM , Zakirova NA , Baïmuradov NS , Sabirova SE , Zakirova FI . Cardiac involvement in adults with echinococcosis. Med Parazitol (Mosk). 2012 Oct-Dec;(4):40-2.
10. Kara SS , Gullu UU . A case of intracardiac echinococcosis . Cardiol Young . 2017 Oct ; Epub 2017 Jun 20.
11. Seth HS , Mishra P , Khandekar JV , Raut C , Mohapatra CKR ¹ , Ammannaya GKK . A Concomitant Intramyocardial and Pulmonary Hydatid Cyst: A Rare Case Report. Braz J Cardiovasc Surg . 2017 Mar-Apr;32(2):138-140.
12. Yaman M , Ates AH , Arslan U , Ozturk H , Aksakal A . A giant cardiac hydatid cyst presenting with chest pain and ventricular tachycardia in a pregnant woman undergoing a cesarean section. Indian Heart J. 2016 Sep. Epub 2016 Apr 28.
13. Rossetti E , Boto A , González Cambaceres C , Ruvinsky S , Sagray E ; colaboradores . Acute arterial embolism as the clinical presentation of a disseminated hydatidosis : case report. Arch Argent Pediatrician . 2018 Aug 1;116(4):e616-e620.
14. Gencheva DG , Menchev DN , Penchev DK , Tokmakova MP . An Incidental Finding of HeartEchinococcosis in a Patient with Infective Endocarditis: a Case Report. Folia Med (Plovdiv) . 2017 Mar 1;59(1):110-113.
15. Sanaei Dashti A , Kadivar MR , Alborzi A , Sadeghi E , Pouladfar GR , Bagherian N , Honar N , Khalifeh M . Analysis of hospital records of children with hydatid cyst in south of Iran. J Parasite Dis . 2017 Dec;41(4):1044-1048.
16. Carmona P , Alonso J , Aparicio S , Zarragoikoetxea I , Ibañez F , Argente P . Cardiac Hydatid Disease: An Uncommon Cause of Cardiac Tumors. J Cardiothorac Vasc Anesth . 2017 Apr;31(2):675-677.
17. Nunes MC , Guimaraes Junior MH , Diamantino AC , Gelape CL , Ferrari TC . Cardiac manifestations of parasitic diseases. Heart . May 2017;103(9):651-658.
18. Mezgar Z Khrouf M , Ben Soltane H , Mahjoub M , Ben Fredj S , Amara A , Jedidi M , Sandid SH , Zaouali S , Waz I , Saada A , Methamem M . Case of Massive Hydatid Pulmonary Embolism Incidentally Discovered in a 56-Year-Old Woman with Posttraumatic Abdominal Pain. case Rep Pulmonol . 2018 May 13;2018:7831910.
19. Aala F , Badali H , Hashemi Fesharaki S , Boromand M , Sotoudeh Anvari M , Davari H , Agha Kuchak Afshari S , Khodavaissy S . Coexistence of aspergilloma and pulmonary hydatid cyst in an immunocompetent individual. J Mycol Med . 2017 Sep;27(3):396-399.
20. Aldahmashi M , Alassal M , Kasb I , Elrakhawy H . Conservative Surgical Management for Pulmonary Hydatid Cyst: Analysis and Outcome of 148 Cases. Can Respir J. 2016;2016:8473070.
21. Prati G , Gatti G , Belgrano M , Pinamonti B , Rauber E , Gripshi F , Pappalardo A , Sinagra G . Disseminated echinococcosis : follow your heart . J Cardiovasc Med (Hagerstown). 2016 Dec;17 Suppl 2:e146-e148.
22. Travin N , Shevchenko Y . Heartechinococcosis : Current problems and surgical treatment. Multimed Man Cardiothorac Surg . 2017 Sep 26;2017.
23. Blanco M , Echevarría JR , Fernández -Gutierrez M , Laguna G . Heart Failure for Superinfected Giant Pericardial Hydatid Cyst. Ann Thorac Surg. 2017 Feb;103(2):e197.
24. Tefera E , Knapp J , Teodori M . Hydatid cyst of the interventricular septum. J Tehran Heart Cent. 2017 Oct;12(4):192-193.
25. Zalaquett E , Menias C , Garrido F , Vargas M , Olivares JF , Campos D Pinochet N , Luna A , Dahiya N , Huete Á . Imaging of Hydatid Disease with a Focus on Extrahepatic Involvement. Glob Cardiol sci Pract . 2017 Mar 31;2017(1):e201709.
26. Kastengren M , Liska J , Svenarud P , Dalén M . Intraventricular Septal Echinococcosis . Ann Thorac Surg. 2017 Jul;104(1):e89.
27. Díaz -Menéndez M , Pérez-Molina JA , Norman FF , Pérez-Ayala A , Monge-Maillou B , Fuertes PZ , López-Vélez R . Management and outcome of cardiac and endovascular cystic echinococcosis . PLOS Negl Trop Dis. 2012 Jan;6(1):e1437.
28. Abad-Torrent A , Sueiras -Gil A , Martínez-Vilalta M , Vallet-Fernández J , Guisasaola-Rabés M . Monitoring of the intraoperative analgesia by pupillometry during laparoscopic splenectomy for splenic hydatid cyst. J Clin Anesth . Feb 2017;36:94-97.
29. Nikmanesh B , Mirhendi H , Mahmoudi S , Rokni MB . Multilocus sequence analysis of Echinococcus granulosus strains isolated from humans and animals in Iran. Exp parasitol . 2017 Dec;183:50-55.
30. Kohansal MH , Nourian A , Rahimi MT , Daryani A , Spotin A , Ahmadpour E . Natural products applied against hydatid cyst protoscolices : A review of past to present. Acta Trop . 2017 Dec;176:385-394 .
31. Şahpaz A , İrez A , Gülbeyaz H , Şener MT , Kök AN . Non-thrombotic Pulmonary Embolism Due to Liver Hydatid Cyst: A Case Report. Balkan Med J. 2017 May 5;34(3):275-277.

32. Inzirillo F, Giorgetta C, Ravalli E. Pericardial echinococcosis : unusual presentation in a non-endemic region. *Asian Cardiovasc Thorac Ann.* 2014 Nov;22(9):1126-7.
33. Kocabay G, Yilmazer S, Korkmaz Y, Karadeniz A, Duran NE. Primary cardiac hydatid cyst presenting as noncompaction cardiomyopathy. *echocardiography.* 2017 Jan;34(1):141-142.
34. Padmanabhan TNC, Kumar K.V.K., Sadiq Azam M, Kumar Bilolika A. Primary echinococcus infection of the heart : a rare type of cystic echinococcosis. *EUR Heart J.* 2017 Aug 1;38(29):2255.
35. Sadashiva N, Shukla D, Devi B.I. Rupture of Intraventricular Hydatid Cyst: Camalote Sign. *World Neurosurg.* 2018 Feb;110:115-116.
36. emam Hadi MA, Najari F, Soleimani L. Sudden Death due to Hydatid Cyst Emboli; a case report. *Emerg (Tehran).* 2018;6(1):e20. Epub 2018 Mar 19.
37. Wadhawa V, Shah J, Doshi C, Ramani J, Lakhia K, Rathod D, Tavar R, Kothari J. Surgical overview of cardiac echinococcosis : a rare entity. *Interact Cardiovasc Thorac Surg.* 2018 Aug 1;27(2):191-197.
38. Agnino A, Lanzone AM, Spira G, Anselmi A. Surgical treatment of left ventricular echinococcosis through the HeartPort technique. *Interact Cardiovasc Thorac Surg.* 2018 Feb 1;26(2):357-359.
39. Sabbagh A, Sonon P, Sadissou I, Mendes-Junior CT, Garcia A, Donadi EA, Courtin D. The role of HLA-G in parasitic diseases. *HLA.* 2018 Apr;91(4):255-270.
40. Mantini C, Capparruccia C, Cademartiri F, Messalli G, Mastrodicasa D, Cinalli S, Cotroneo AR, Caputo M. Uncommon Isolated Unilocular Myocardial Cyst in a Dog-Friendly Young Female Patient - Multimodality Imaging. *Circ J.* 2017 Jun 23;81(7):1056-1058.
41. Gurzu S, Beleaua MA, Eged-Zsigmond E, Jung I. Unusual Location of Hydatid Cysts: Report of Two Cases in the Heart and Hip Joint of Romanian Patients. *Korean J Parasitol.* 2017 Aug;55(4):429-431.
42. Singh A, Sharma R, Garg A, Nanda NC, Elsayed M, Taher A, Bulur S. Usefulness of bubble study in echocardiographic diagnosis of contained rupture of hydatid cyst in the right ventricular outflow tract. *echocardiography.* 2016 Sep;33(9):1402-8.
43. Atayi Z, Borji H, Moazeni M, Saboor Darbandi M, Heidarpour M. Zataria multiflora would attenuate the hepatotoxicity of long-term albendazole treatment in mice with cystic echinococcosis. *Parasitol Int.* 2018 Apr;67(2):184-187.
44. El Kharras A, Atmane M, El Fenni J, Chaouir S, Amil T. [Cardiac and renal hydatid disease--contribution of imaging: report of a case]. *Pan afr Med J.* 2014 Jun 18;18:153.
45. Ouzzad O, Kechna H, Moudden MK, Chkoura K, Hanafi SM. [Cardiac arrest during liver hydatid cyst surgery]. *Pan Afr Med J.* 2015 Sep 15;22:32.
46. Zaghba N, Maiouak S, Benjelloun H, Yassine N, Bakhatar A, Bahlaoui A. [Chronic pulmonary heart disease complicating hydatid embolism]. *Med Mal Infect.* 2015 Jan-Feb;45(1-2):52-4.
47. Martín- Izquierdo M, Martín- Trenor A. [Hydatidosis simulating a cardiac tumor with pulmonary metastases]. *Cir Cir.* 2016 Jul-Aug;84(4):318-23.
48. Sidler X, Eichhorn J, Geiser V, Bürgi E, Schüpbach G, Overesch G, Stephan R, Schmitt S, Hässig M, Sydler T. [Lung and pleural lesions before and after implementation of a national eradication program against enzootic pneumonia and actinobacillosis as well as changes of slaughter carcass organs in slaughter pigs in Switzerland]. *Switzerland Arch Tierheilkd.* 2015 Dec;157(12):665-73.
49. Dianka MB, El Hamdani T, Kaba I, Naja A, Ibahioin K, El Azhari A. [Multiple cerebral hydatid cysts of cardiac origin: report of a case]. *Pan afr Med J.* 2015 Sep 9;22:15.
50. Senhaji L, Karhate M, Amara B, El Biaze M, Benjelloun MC, Tizniti S, Lahlou I, Serraj M. [Multiple lung nodules and mediastinal widening of unusual etiology]. *Rev Mal Respir.* 2015 Mar;32(3):291-5.
51. Fenane H, Maida el M, Bouchikh M, Lamboni D, Achir A, Ouchen F, Oyali M, Caidi M, Al Aziz S, Benosman A. [Pericardial hydatidosis]. *Pan Afr Med J.* 2015 Apr 16;20:375.
52. Il'inov VN, Kozlov BN, Kuznetsov MS, Panfilov DS, Nasrashvili GG, Lelik EV, Katkov VA, Samtsova TM. [Surgical treatment of patient with echinococcus cyst of left ventricle apex]. *Khirurgiia (Mosk).* 2014;(11):70-2.
53. Bayramov F, Emet S, Dadashov M, Umman B, Buğra Z. A case of an atypically located cardiac hydatid cyst. *Anatol J Cardiol.* 2015 Sep 1;15(9):E24-5.
54. Yildiz CE, Sinan ÜY, Yildiz A, Çetin G, Küçükoğlu S. A Case of Isolated Cardiac Hydatid Cyst that Mimics Lymphoproliferative Malignancy. *echocardiography.* 2015 Jun;32(6):1036-9.
55. Birincioglu CL, Kervan U, Tufekcioglu O, Ozen A, Bardakci H, Kucuker SA, Saritas A. Cardiac echinococcosis. *Asian Cardiovasc Thorac Ann.* 2013 Oct;21(5):558-65.
56. Parvizi R, Namdar H, Bilehjani E, Bayat A, Sheikhalizadeh MA. Simultaneous operation of hydatid cyst of the heart and liver: a case report. *J Cardiovasc Thorac Res.* 2013;5(3):127test-128.
57. Elhattaoui M., Charel N., Bennis A. et al. Cardiac hydatid cysts: report of 10 cases // *Arch. Mai. Coeur. Vaiss.* - 2006. - Vol. 99, No. 1, - P. 19-25.
58. Jerbi S, Romdhani N., Tarmiz A. et al. Emboligenously hydatid cyst of the right heart // *Ann Cardiol Angeiol.* - 2008 Feb;57(1):62-5.
59. El-On J. Benzimidazole treatment of cystic echinococcosis. // *Acta Trop.* J. - 2003;85:243-52.
60. Solano Ramirez M., Urbietta Echezarreta MA, Alvarez Frias M. T. et al. Cardiac tamponade caused by hydatid pericarditis // *An. Med. Interna.* - 2005. - Vol. 22, No. 7. -, P. 326-328.



ISSN: 2181-0974

DOI: 10.26739/2181-0974

ЖУРНАЛ КАРДИОРЕСПИРАТОРНЫХ ИССЛЕДОВАНИЙ

ТОМ 5, НОМЕР 2

JOURNAL OF CARDIORESPIRATORY RESEARCH

VOLUME 5, ISSUE 2

Контакт редакций журналов. www.tadqiqot.uz

ООО Tadqiqot город Ташкент,
улица Амира Темура пр.1, дом-2.

Web: <http://www.tadqiqot.uz/>; Email: info@tadqiqot.uz

Тел: (+998-94) 404-0000

Editorial staff of the journals of www.tadqiqot.uz

Tadqiqot LLC the city of Tashkent,
Amir Temur Street pr.1, House 2.

Web: <http://www.tadqiqot.uz/>; Email: info@tadqiqot.uz

Phone: (+998-94) 404-0000