

UDK: 616-091 (075.8).

## MACRO- AND MICROSCOPIC FEATURES OF THE FATER PAPILLA IN ANIMALS



Dekhkanov Toshpulat Dekhkanovich, Rakhmanov Zafarjon Mamadiyevich,  
Rakhmonova Khabiba Nurullayevna  
Samarkand State Medical University, Republic of Uzbekistan, Samarkand

## ҲАЙВОНЛАРДА ФАТЕР СЎРҒИЧИНИНГ МАКРО- ВА МИКРОСКОПИК ХУСУСИЯТЛАРИ

Дехканов Тошпулат Дехканович, Рахманов Зафаржон Мамадиевич, Рахмонова Хабиба Нуруллаевна  
Самарқанд давлат тиббиёт университети, Ўзбекистон Республикаси, Самарқанд ш.

## МАКРО- И МИКРОСКОПИЧЕСКИЕ ОСОБЕННОСТИ ФАТЕРОВА СОСОЧКА

Дехканов Тошпулат Дехканович, Рахманов Зафаржон Мамадиевич, Рахмонова Хабиба Нуруллаевна  
Самаркандский государственный медицинский университет, Республика Узбекистан, г. Самарканд

e-mail: [xabiba\\_1977@mail.ru](mailto:xabiba_1977@mail.ru)

**Резюме.** Ўт пуфаги мавжуд ва мавжуд бўлмаган ҳайвонларда Фатер сўргичининг қиёсий морфологияси ўрганилди. Фатер сўргичининг қалинлигида ўт пуфаги мавжуд ҳайвонларда мураккаб бурмалар тармоғига эга бўлган ампула борлиги аниқланди, бу эса ўт пуфаги мавжуд бўлмаган ҳайвонларда кузатилмайди.

**Калит сўзлар:** Фатер сўргичи, қиёсий морфология.

**Abstract.** The comparative morphology of the Fater papilla of animals with and without gall bladder was studied. It was established that those animals that have a gall bladder larger than the Fater papilla have an ampoule with a complex network of folds, which is not the case for those who do not have a gall bladder.

**Keywords.** Fater papilla, comparative morphology.

**Introduction.** The congenital absence of any organ is a severe developmental anomaly and often leads to serious consequences. However, there are organs that are not available in all representatives of vertebrate animals similar in terms of the conditions of existence and the nature of nutrition. These organs include the gallbladder. Some animals (rats, horses, camels, elephants, rhinos, etc.) and birds (pigeons, turtledoves, ostriches, etc.) do not have it. This great biological problem, which attracts the attention of researchers in this century, is far from its final solution. However, the literature data concerning the functional significance of the gallbladder indicate that it is involved in the regulation of the digestive activity of the small intestine, affects the functional activity of the sphincter of Oddi [3, 5, 9]. There are works devoted to the peculiarities of the structural organization of the major duodenal papilla [10], which indicate the presence of a complex of sphincters. There are works concerning the role of the gallbladder [1, 4, 7]. Naturally, the question arises, how does the compensation of these functions occur in those animals that do not have a gallbladder? The gallbladder by its contraction (together with the common bile duct) creates pressure that contributes to the opening of the sphincter of Oddi. Therefore, it can be assumed that

in vertebrates that do not have a gallbladder, the sphincter apparatus of the terminal section of the common bile duct should also have its own characteristics. According to the literature data [2, 6, 8], the ampulla contains 3-5-tier semilunar folds that form valves. There are also comparative morphological works devoted to this issue [5, 7, 8]. The above data suggest that the reasons for the absence of the gallbladder in a number of vertebrates have not been fully established, and this major biomedical problem is far from being finally resolved.

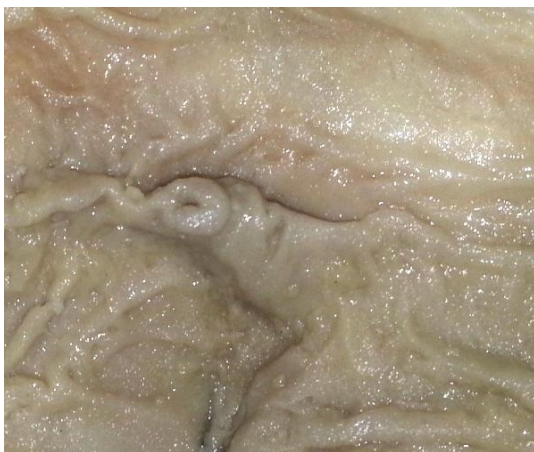**Purpose of the study.** The study of comparative macroscopic and microscopic features of the papilla of Fater in mammals with and without a gallbladder.

**Material and methods of study.** The material for our research was the papillae of 10 rats and 6 horses (do not have a gallbladder), 12 rabbits and 11 representatives of cattle (have a gallbladder). In horses and in representatives of cattle, the structure of the Fater papilla was studied macroscopically under a binocular magnifying glass. Fater papilla of rabbits and rats was studied microscopically by obtaining serial sequential sections. The materials were fixed in 12% neutral formalin, neutralized with a saturated solution of sodium tetraborate. Histological pro-

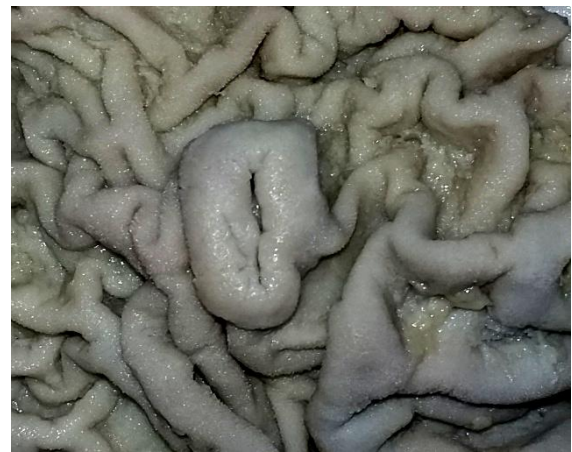cessing of the material and filling in paraffin was carried out according to the generally accepted scheme. Serial successive sections of the material were stained with hematoxylin-eosin, according to the Van Gieson method and impregnated according to Grimelius.

**Research results.** In representatives of cattle, the longitudinal fold of the duodenum is distinct, and at the top there is a papilla of Vater, the mouth of the ampulla of which is in the form of an oval hole (Fig. 1A). In the thickness of the longitudinal fold there is an ampulla, in the form of an expanded part of the channel of the intra-wall section of the duct. The expansion cavity has an oval shape. In horses, the longitudinal fold of the duodenum is not visible. The channel of the intramural part of the bile duct has the same diameter throughout. Vater's papilla has the shape of the end of a tube with wrapped edges. The mouth has a slit-like shape (Fig. 1B). The longitudinal fold of the duodenum of adult rabbits at the distal end form the papilla of Vater. In the lower, most protruding part of the longitudinal fold, one can see the mouth of the ampoule in the form of a pinhole. Below the mouth, the longitudinal fold narrows and gradually becomes indistinguishable. The common bile duct "enters" the outer wall of the duodenum at an angle of 30° to 48°. First, the common bile duct attaches to the outer wall of the duodenum and gradually sinks into it. At this level, the mucous membrane of the common bile duct forms longitudinal folds. The muscular membrane of the intestine and the common bile duct are connected in a peculiar way. The outer longitudinal layer of the muscular layer of the duodenum merges with such a shell of the common bile duct, forming a common muscle layer. The mucous membrane of the duct forms wide folds of longitudinal orientation. As the common bile duct sinks, the muscular membrane of the intestine and the duct merge completely and the duct remains inside this membrane. It should be noted that in this place, almost the entire muscular membrane is located circularly, forming its own sphincter of the common bile duct. At the same time,

it is impossible to separate the muscular membrane of the duodenum and the common bile duct, which suggests that they function in a complex manner. At this level, the folds of the mucous membrane become high, acquire various configurations, and anastomoses appear between them. The lumen of the duct expands compared to the previous level, and begins to form the ampulla of the Vater papilla. Further, the common bile duct gradually penetrates the muscular membrane of the intestine and the bulk of this membrane is located laterally from the duct. The lumen of the duct expands, forms an ampulla, and the folds of the mucous membrane become long, anastomosing with each other, as if they divide the walls of the ampulla into separate chambers of various configurations. The mucous membrane of the common bile duct becomes much thicker and glands appear in it. Gradually, the muscular membrane from the side of the lumen of the intestine becomes thinner, and the ampoule is surrounded on three sides by the mucous membrane of the duodenum. This intestinal lining also contains many mucous glands. Further, the lumen of the ampoule becomes wide, all the folds anastomize with each other and they form a single complex (Fig. 2). The muscular membrane from the side of the intestinal cavity becomes thinner. The ampoule has a maximum width. It should be noted that when studying micropreparations of the internal relief of the ampulla of the Vater papilla from fixed and non-fixed material, a significant difference was revealed. When fixing the material, apparently, some wrinkling of the material occurs under the action of the fixative, and when studying micropreparations from this material, the folds of the ampulla of the papilla of Vater seem to be compacted and the distance between them (the free cavity of the ampulla) is relatively wider (Fig. 2.2). On micropreparations prepared in a cryostat from fresh (non-fixed) material, the folds have a high density and the distance between them is insignificant (Fig. 2.1).



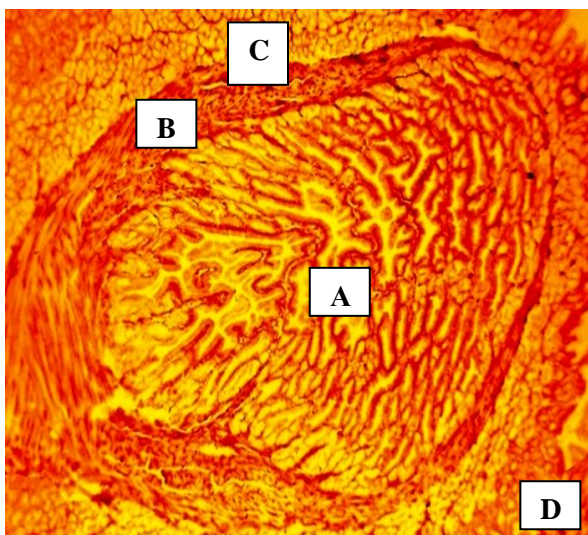
A



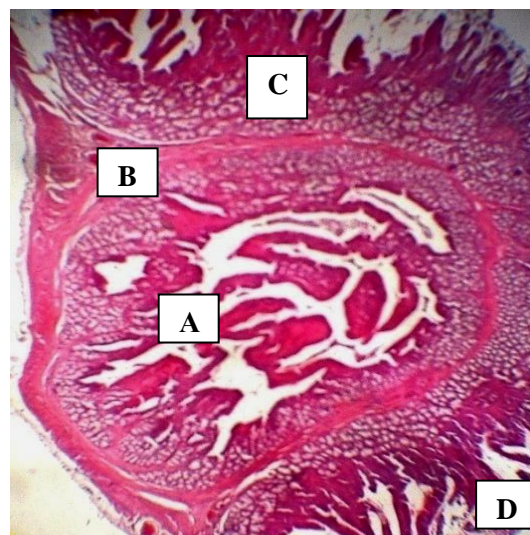
B

**Fig. 1.** Macroscopic structure of the Vater papilla of a bull (A) and a horse (B). macropreparation. MBS. Ob.4, ok.6.





1



2

**Fig. 2.** Cryostatic (1) and paraffin (2) sections of the ampulla of the Vater papilla of an adult rabbit. 1 impregnation according to Grimelius. 2-staining with hematoxylin-eosin. Ob.20, ca. 10. A-cavity of the ampoule with folds. B-muscular membrane of the ampoule. C- submucosa of the duodenum with Brunner's glands, D- cavity of the duodenum.

This is also confirmed by our morphometric studies: if the ratio of folds and free space on micropreparations from a fixed material is from 1.2 to 1.6 conventional units, then in preparations from non-fixed material these figures are respectively 1.8 and 1.9. In rats, the intramural part of the common bile (hepatic) duct, as well as in horses, does not form a pronounced ampulla with complex mucosal folds. There is a slight expansion of the duct at the mouth. However, the mucous membrane of this expansion does not have pronounced folds, the cavity is free. The aperture is slit-like and mobile folds are also not visible in it.

Thus, in rabbits and cattle that have a gallbladder, the papilla of Vater forms a pronounced ampulla (ampulla of Vater) with a complex network of folds, while in rats and horses that do not have a gallbladder, such an ampulla is not found.

#### Literature:

1. Dekhkanov T.D., Oripov F.S., Dekhkanova N.T., Rakhmonova H.N. Features of the structural organization of the ampulla of Vater's papilla in animals with different nutritional patterns // Scientific journal, 2021. No. 02 (57). pp. 94-96.
2. Dundarov Z.A., Gavrichenko V.I., Golubeva N.N. Some features of the morphology of the major duodenal papilla in humans and dogs // Problems of health and ecology - 2007. - No. 4. - P.73 - 77.
3. Horiguchi S., Kamisawa T. Major duodenal papilla and its normal anatomy // Dig Surg. 2010, 27(2): 90 - 3.
4. Kostyrkina V.V. Features of the structural organization of the major duodenal papilla // Electronic scientific and educational bulletin "Health and education in the XXI century" - 2006. - No. 8. - P.390.

5. Oripov F.S., Rakhmonov Z.M., Dekhkanov T.D. Comparative topography of relief formations of the mucous membrane of the ampulla of Vater's papilla // New Day in Medicine, 2020. No. 2/1. pp. 203-205.
6. Pokhabova E.Yu., Belova G.V. Modern view on non-tumor stenosing lesions of OBD - etiology and pathogenesis, diagnostic possibilities. Systematic review // Experimental and clinical gastroenterology - 2012. - No. 06. - S. 69 - 75.
7. Rakhmonov Z.M., Dekhkanov T.D. Morphology of the structural components of the mucous membrane of the ampulla of Vater's papilla // Problems of biology and medicine, 2016. No. 4 (91). pp. 146-148.
8. Tyuryumin Ya.L., Shanturova V.A., Tyuryumina E.E. The role of the gallbladder // Bulletin of the VSNC SO RAMS 2011, - No. 4, - part 2 .-p.347-352.
9. Vinnik Yu.S., Serova E.V., Miller S.V., Mukhin S.P. Diagnostic criteria for dysfunction of the sphincter of Oddi after cholecystectomy // Annals of Surgery. - 2012. - No. 6. -S. 5-8.
10. Zimatkin S.M., Markovets N.I. Comparative anatomy of the liver and bile ducts of humans and rats // Bulletin of VSMU - 2016. - V.15. No. 3. P.18 - 23.6.

#### МАКРО- И МИКРОСКОПИЧЕСКИЕ ОСОБЕННОСТИ ФАТЕРОВА СОСОЧКА

Дехканов Т.Д., Рахманов З.М., Рахмонова Х.Н.

**Резюме.** Изучена сравнительная морфология фатерова сосочка у животных, имеющих и не имеющих желчный пузырь. Установлено, что у тех животных, которые имеют желчный пузырь в толще фатерова сосочка имеется ампула со сложной сетью складок, чего нет у животных не имеющих желчный пузырь.

**Ключевые слова:** Фатеров сосок, сравнительная морфология.