

Isломов Нуриддин Комил угли¹, Мустафакулов Ишназар Бойназарович¹, Жулбеков Комил Исломович²

1 – Samarkand State Medical University, Republic of Uzbekistan, Samarkand;

2 – Samarkand branch of the Republican Scientific Center for Emergency Medical Care, Republic of Uzbekistan, Samarkand

ЛАПАРОСКОПИЯДА МАКРОПРЕПАРАТЛАРНИ ЭКСТРАКЦИЯ ҚИЛИШНИНГ ТУРЛИ УСУЛЛАРИ ҲАҚИДАГИ ШАРҲ

Исломов Нуриддин Комил угли¹, Мустафакулов Ишназар Бойназарович¹, Жулбеков Комил Исломович²

1 – Самарқанд давлат тиббиёт университети, Ўзбекистон Республикаси, Самарқанд ш.;

2 – Республика шошилиш тиббий ёрдам илмий маркази Самарқанд филиали, Ўзбекистон Республикаси, Самарқанд ш.

ОБЗОР РАЗЛИЧНЫХ МЕТОДОВ ЭКСТРАКЦИИ МАКРОПРЕПАРАТОВ ЛАПАРОСКОПИИ

Исломов Нуриддин Комил ўгли¹, Мустафакулов Ишназар Бойназарович¹, Жулбеков Комил Исломович²

1 – Самарқандский государственный медицинский университет, Республика Узбекистан, г. Самарқанд;

2 – Самарқандский филиал Республиканского научного Центра экстренной медицинской помощи, Республика Узбекистан, г. Самарқанд

e-mail: zafarbak1992@gmail.com

Резюме. Ҳозирги кунда лапароскопик операциялар кўпга тиббий муассасаларнинг кундалик амалиётига мустаҳкам жойлашган. Дунё бўйлаб кўпга мамлакатларда олиб борилган комплекс рандомизация қилинган тадқиқотлар асосида лапароскопик операцияларнинг очиқ усуллар билан солиштирилганда асосий афзалликлари шакллантирилди, яъни операциядан кейинги оғриқларнинг камроқлиги, оғриқларни кетказиш воситаларининг сарфи камайиши, операциядан кейин стационарда бўлиш вақти қисқараши, тезда одатий ҳаётга ва ишга қайтиши, яхши косметик таъсир, операциядан кейинги герниялар даражасининг пастлиги.

Калим сўзлар: Лапароскопия, миниинвазив хирургия, лапароскопик хирургия, долихосигма.

Abstract. In present time laparoscopic operational interventions have become firmly established in the daily practice of most medical institutions. Based on comprehensive randomized trials conducted in many countries peace, were formulated main advantages laparoscopic operations By relation To open methods execution similar interventions, A exactly smaller degree expressions painful sensations after operations, decrease consumption painkillers, funds, more short term stay V in hospital after operations, fast return To habitual life And work, good cosmetic effect, low frequency development postoperative hernias.

Key words: Laparoscopy, mini invasive, laparoscopic surgery, dolichosigma.

Because laparoscopy V present time covers wide spectrum operations such as removal of large tumors (fibroids, large tumors ovaries), appendectomy, ectopic pregnancy, splenectomy, resection thick intestines And some other, most important is reduction of the volume of a tumor or tissue and its removal from the peritoneal cavity through cut With minimal possible size. On initial stages formations laparoscopy, myomectomy was performed rarely, But Now, With years, With improvement technologies overlays seams And skills, laparoscopic myomectomy becomes All more popular present time dimensions And quantity subject removal myomas Not are contraindications To laparoscopic operations, contraindication To laparoscopic removal myomas on given moment V more depends on the degree from surgeon's experience.

There are currently a number of methods available for removing tissue from abdominal cavities at laparoscopy. Choice methods extractions is carried out V dependencies from deleted organ, his size, type tumors, preferences surgeon, availability tools, economic efficiency. In this article we will describe all the methods of tissue extraction at laparoscopy.

Extraction directly through trocar , extension laparoports. Trocars size 10 mm are used almost in all laparoscopic operations. These same trocars Can use For removals such fabrics How capsules cysts, uterine pipes, fetus at ectopic pregnancy, appendix And etc. Usage tool diameter 5 mm through adapter 10/5 mm With trocar 10 mm allows easily and quickly remove tissue.

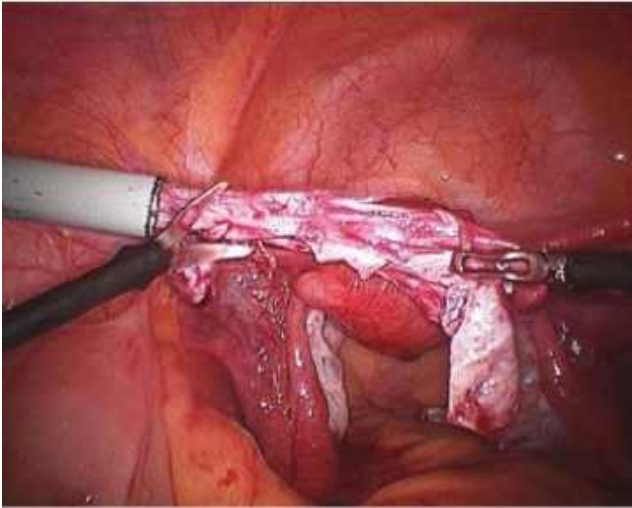


Fig. 1. Spiral cut capsules cysts For decrease her sizes

If the size of the tissue to be removed does not match trocar it is possible to reduce the size of the tissue using spiral incisions along the length of the tissue, which facilitates tissue extraction through the laparoprot diameter 10 mm.

In cases where the diameter of all trocars during surgery is 5 mm For extensions port possible replacement trocar 5mm on trocar With diameter 10 mm. Sometimes at impossibilities extractions fabrics even through 10 mm trocar (For example empyema appendix, gallbladder bubble) Maybe application port dilator 10/20 mm. At operations on lower floor abdominal cavities For extractions usually use laparoprot V lower left quadrant of the abdomen, because it is usually not visible because it is located in the area bikini, in cases with cholecystectomy, a laparoprot is usually used under xiphoid process due to the lower risk of developing postoperative hernias.

Colpotomy. It is a fairly simple and effective technique for extraction macropreparation. This technique is used mainly for extraction myomas And at neoplasms ovaries, macropreparation at this fits V endobag. Essence of this method consists of V volume What Douglas space is used For extractions macropreparation. Progress laparoscopic surgery was hampered by difficulties arising during extraction fabrics V cases inconsistencies their sizes With dimensions traditional trocars. Problem concluded V volume, What at transabdominal removal fabrics was required big cut, What drove on No All advantages laparoscopy, V That time How at transvaginal removal was observed leakage CO₂. These technical the difficulties were overcome with the release of CCL (Colpo-Coeliocirurgie Lausanne) vaginal extractor (Figure 3) consisting of a trocar equipped with spherical head at one end. The round surface of the sphere is good adjacent To back vault vagina, on surfaces has horizontal groove, which serves a guide-orienteer V moment cutting peritoneum.

Vaginal extractor or forceps With with a sponge on at the end are introduced intravaginally With purpose prevention leaks gas And For Togo to define place colpotomy. WITH with help monopolar hook, with scissors or laparoscopic with a spatula is being done cut over

extractor CCL, between two uterosacral ligaments (Drawing 5). After an incision is made on the posterior vaginal fornix, 10-mm forceps are inserted, the macropreparation or endobag is captured and removed. After this, the incision is made can be sutured vaginally or laparoscopically. The procedure is safe because passes under endoscopic visual control. The above method is used V basically For extractions ovaries, organic cysts, fruit at ectopic pregnancy, myoma.

Application endobag. Endobag is widely used in such operations as laparoscopic oophorectomy And cystectomy For prevention outpourings contents macropreparations. There is evidence that the use of bags endobag reduces time operations. Outpouring contents macropreparations V abdominal cavity usually is happening or in time operations, or V moment removals his from abdominal cavities. IN cases With cysts ovaries It is recommended not to puncture or aspirate the contents of the cyst to prevent the dissemination of malignant cells. In such cases ideal the solution is application Endobag.

Endobag there are V free sale, can be entered V abdominal cavity through a laparoprot in the left lower quadrant of the abdomen, a laparoprot in umbilical areas, So same endobag Maybe be entered through vaginal CCL extractor. After insertion into the abdominal cavity, the endobag unfolds. Cyst, appendix, or other organ that needs to be removed placed inside the package. The contents of the cyst, gall bladder can be sucked out to reduce the volume of tissue removed, but the manipulation should be performed inside the Endobag. This method, when properly performed, prevents the contents of the macroscopic preparation from leaking into the abdominal cavity. After this, the thread is tightened to close the lumen of the sac. Macropreparation can be removed through laparoprot sites on the anterior abdominal wall or at help vaginal CCL extractor transvaginally V dependencies from performed operations And preferences surgeon.

In developing countries, homemade bags are used instead of endobags evacuation systems made of sterile gloves, condoms, plastic bags. Another modification of the homemade endobag is sterile gloves With imposed purse-string seam at places entrance And bandaged at the base of the fingers.

After placing the cyst and gallbladder into the bag, the pouch is tightened. An option with suction of the contents of the macropreparation to reduce is possible. its size, the suction procedure is strictly performed inside the bag for prevention of leakage of the contents of the macropreparation. Extraction of the sac can be performed by traction on a thread either transvaginally or through laparoprot on front abdominal wall. This method is economically effective V conditions absence V free sale systems Endobag.

Described cases applications sterile condoms V quality Endobag. Application their justified V cases absence Endobag V freesale. Advantage extractions fabrics at help condom is lubrication applied on surface condoms, What makes it easier the process of its sliding through the tissues of the anterior abdominal wall traction.

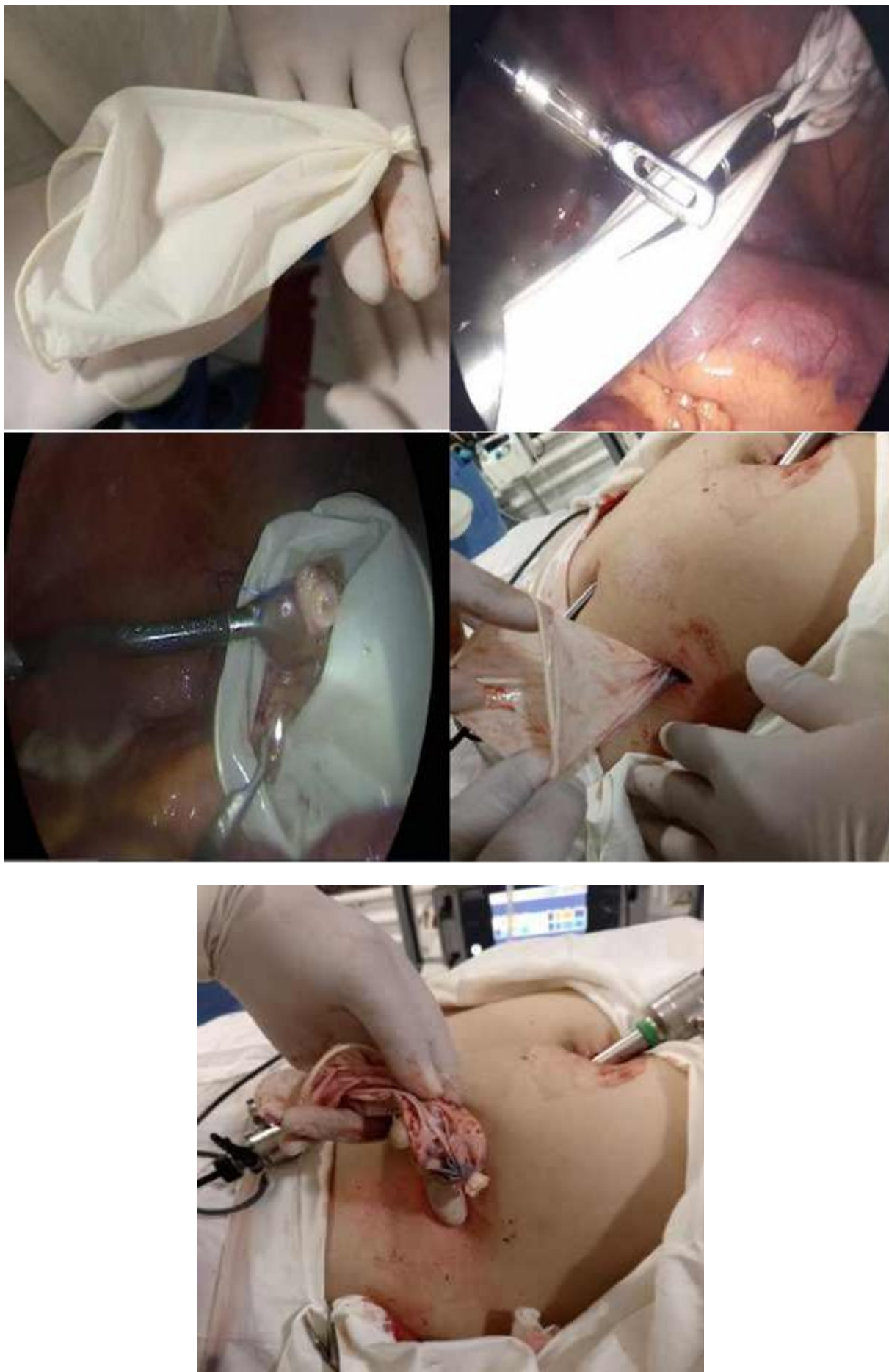

Fig. 2. Extraction of the appendix through a 10 mm diameter trocar mm in the left iliac region using sterile gloves in quality endobag

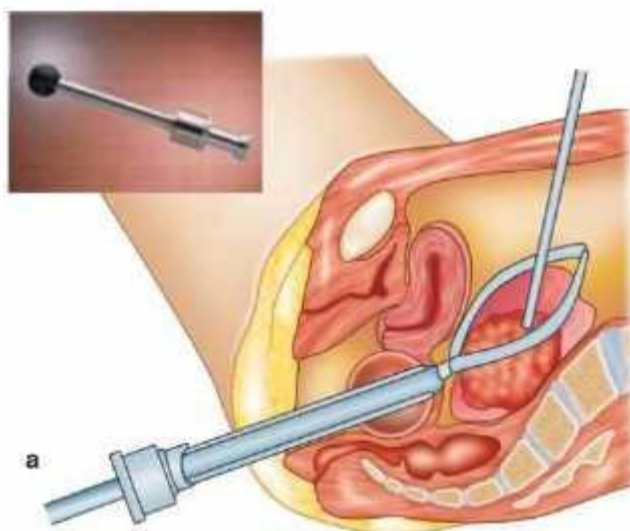


Fig. 3. Vaginal CCL extractor

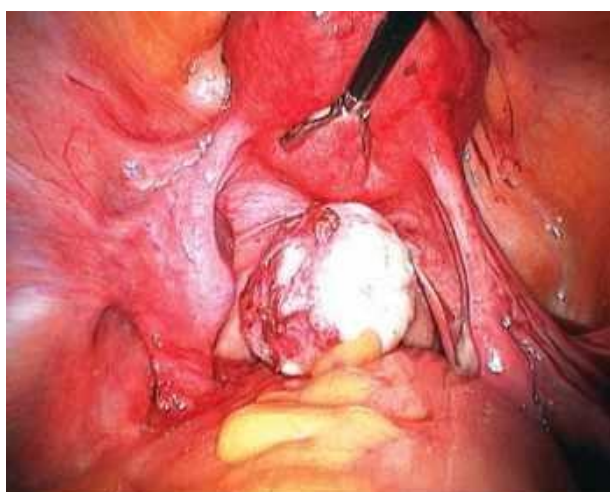


Fig. 4. Myoma subject removal

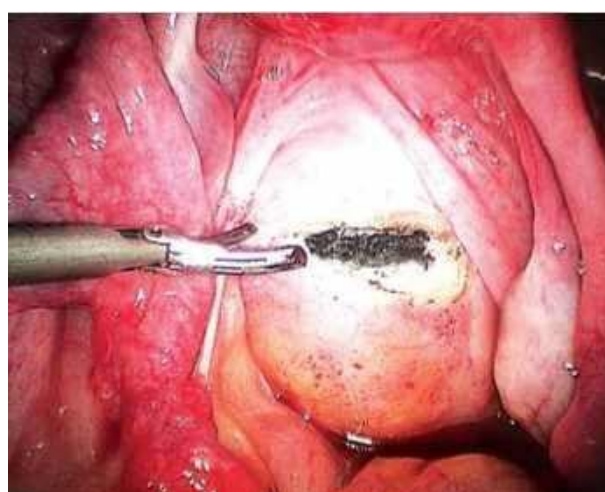


Fig. 5. Section over extractor between two uterosacral ligaments

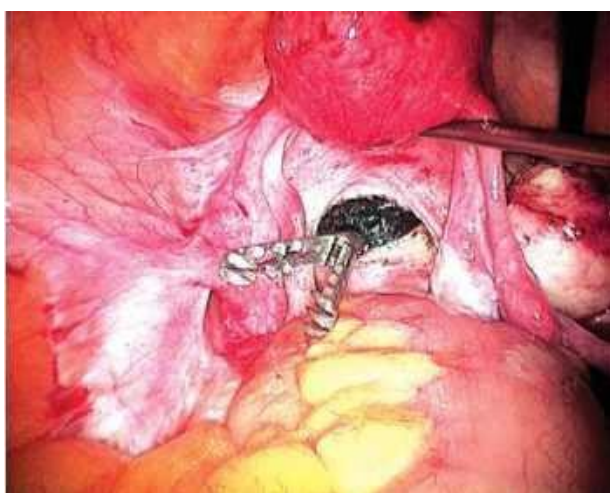

Fig. 6. Introduction clamp through Extractor

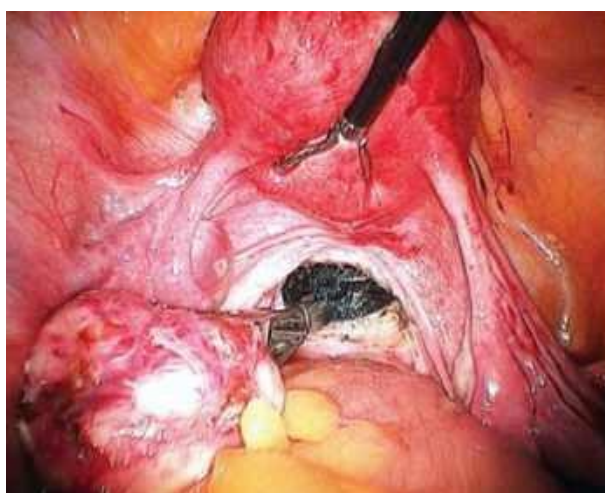


Fig. 7. Capture macropreparation

Electromechanical morcellation. Laparoscopic operations By about removals big formations such How myoma or uterus By this day are problem minimally invasive surgery. Despite the fact that at the moment there are many methods extractions fabrics specially intended For removals large-sized macropreparations, all of them

have disadvantages in the form of the fact that What procedure takes up many time, often requires extensions cut or even Sometimes required additional cut, How For example V case transvainal removals drugs. IN 1973 year was developed first V world manual morcellator For grinding And removals samples at laparoscopic operations.

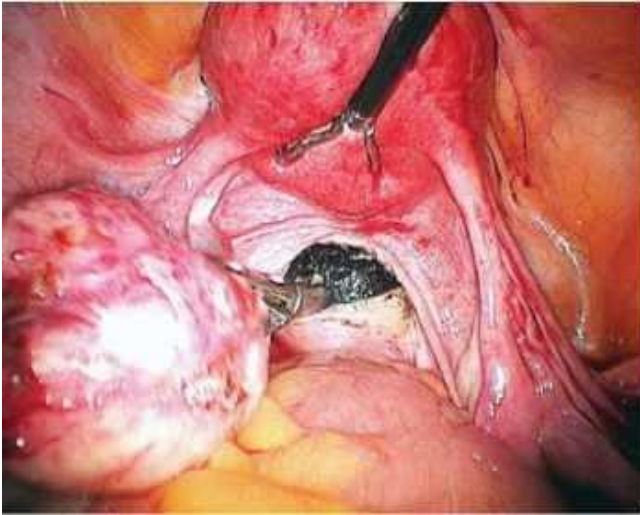


Fig. 8. Moment extractions Macropeparation

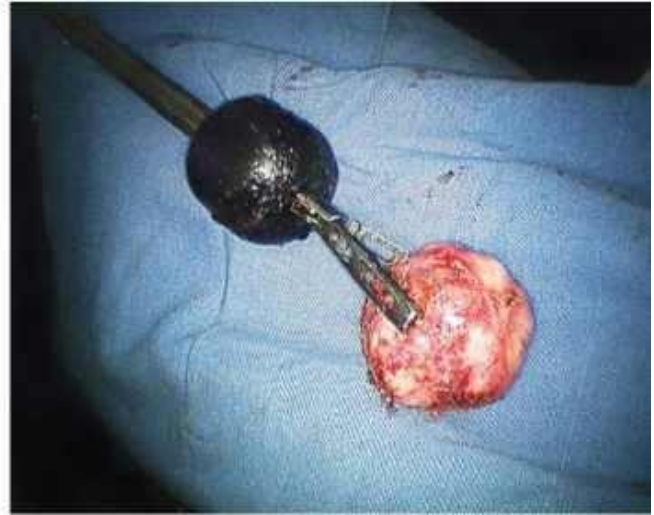

Fig. 9. Macropeparation after extractions



Fig. 10. Bandaging thread at grounds fingers



Fig. 11. Fingers cut off at the base

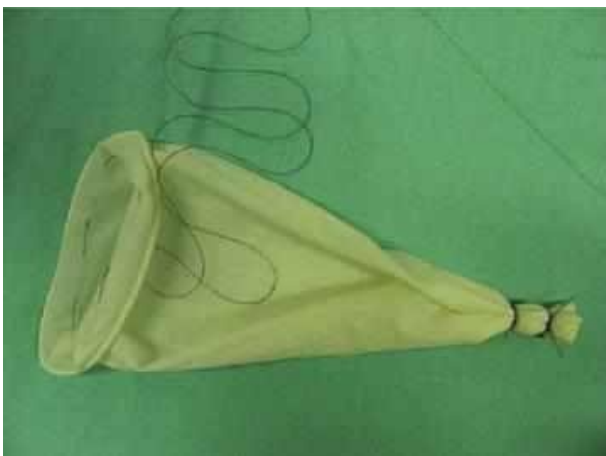

Fig. 12. Superimposed purse-string seam on site

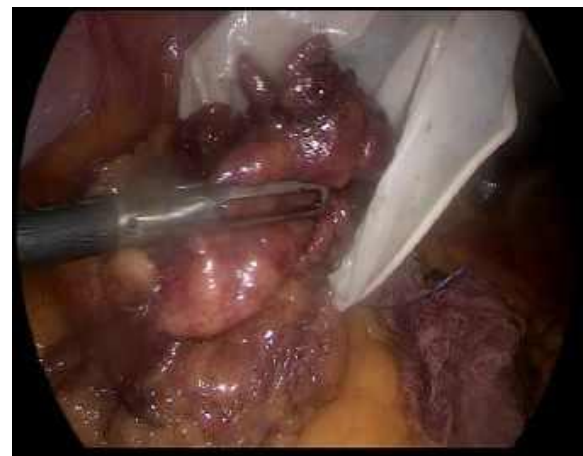

Fig. 13. Macropeparation fits Ventrance to homemade pouch

Despite on This even For removals small samples required a considerable amount of time, since the instrument worked due to manual efforts. In 1993 year morcellator Steiner produced revolution V laparoscopic surgery.

In difference from manual morcellator electromechanical tool allowed delete even big macropeparations for counted minutes without additional cuts.

Electromechanical morcellator consists of from cutting tubes working for check engine, which Maybe be introduced V abdominal cavity through installed trocar. Speed rotations Maybe be selected preliminary, tool is activated pedal. Exists opportunity rotations By hourly arrow, against hourly arrows, rotation with oscillatory movements. The toothed clamp is inserted into the abdominal cavity through the cutting tube.

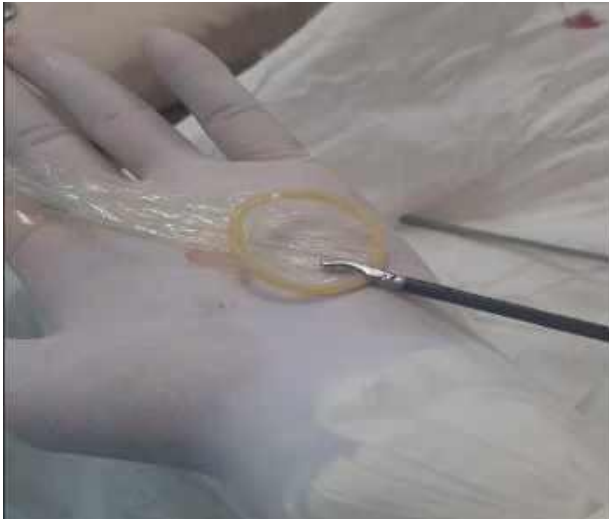

Fig. 14. Preliminary expanded

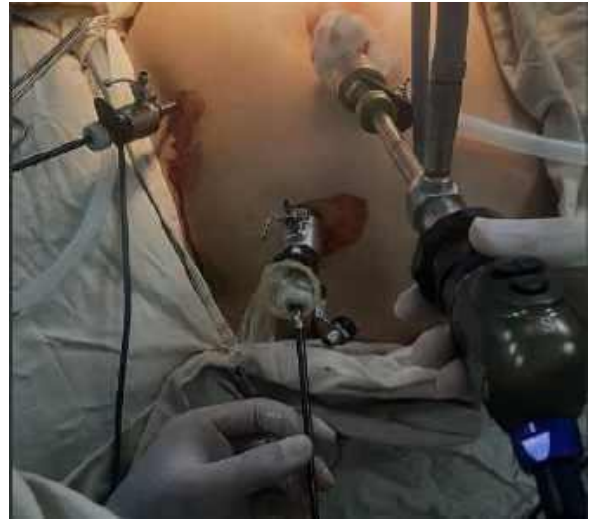

Fig. 15. Introduction into the abdominal cavity condom through trocar 10 mm V left lower quadrant

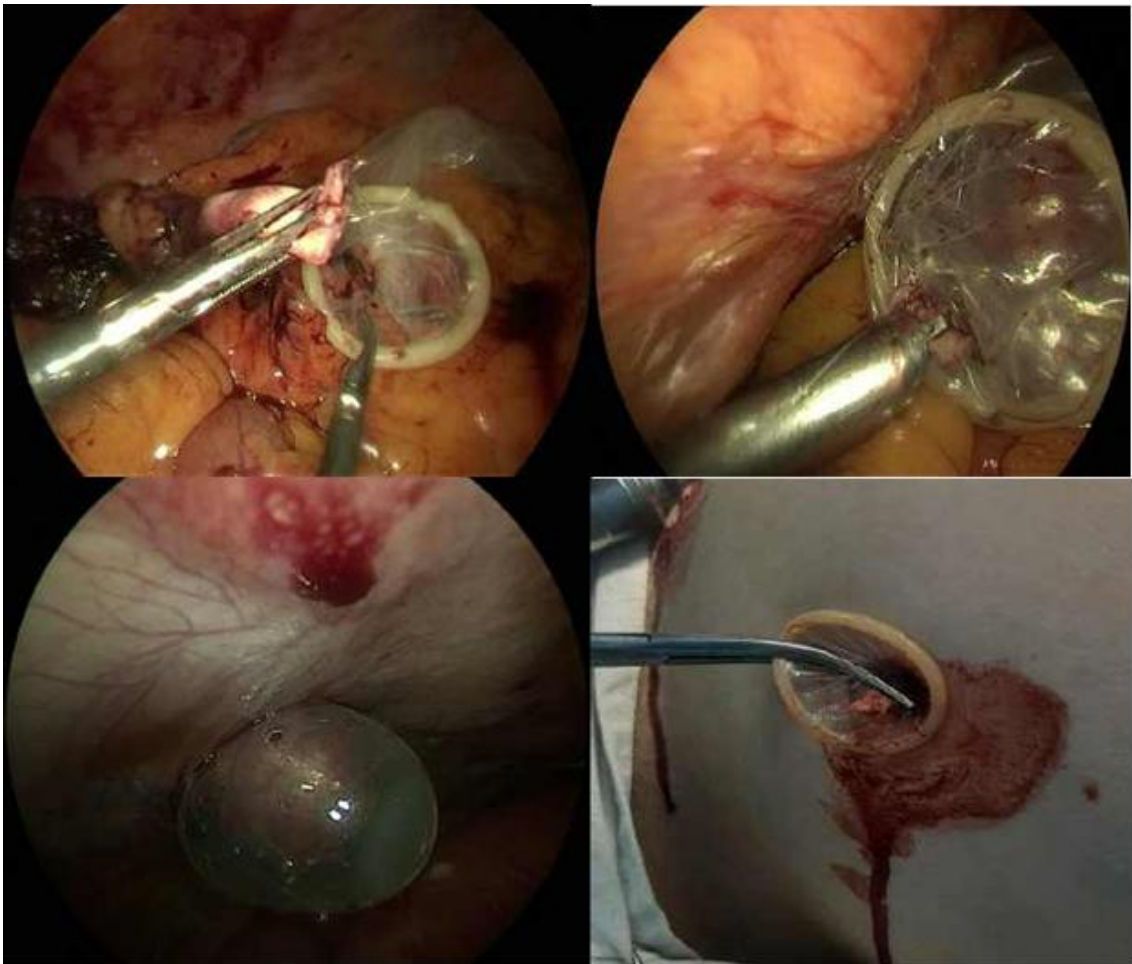


Fig. 16. Moment extractions condom With vermiform process inside

After the macropreparation is captured by forceps The forceps are pulled back towards the cutting edge of the rotating morcellator. The fabrics are cut in the shape of a cylinder (Fig. 20). In this way, even a large macro specimen can be removed within a few minutes without additional incisions.

The use of a morcellator also provides safety fabrics For subsequent histological research.

To remove larger macropreparations there were formations The Rotocut tool from Karl Storz is proposed (Fig. 15). In addition to usual 12 mm port offered 15 mm

ports For more large macropreparations. The device is given V action for check super powerful electric motor. Blade protected safety mechanism, which prevents any unintentional cutting of the fabric. New Rotocut has multitude additional functions security And more speed in comparison With predecessors.

Important economic aspect is opportunity reusable use. Hence, to this reusable device is given away preference before disposable his analogues. However, follows have in view of, What despite on disability use, tool For

morcellation Gynaecare So same uses big in demand (Fig. 16).

After morcellation it is important the stage of the operation is closing defect abdominal cavities For prevention development Richterovskiy infringement, since this method of extraction uses laparoports with diameter 12-15 mm. Used special needle For closings defect from laparoport (Figure 21, 22). After removing the morcellator, the needle is inserted into abdominal cavity through one edge of the wound, while the needle is inserted into the abdominal cavity together with the vicryl thread. In the abdominal cavity the thread is removed from needles and the needle is removed. The needle is reinserted through the opposite edge wounds, But already without threads. IN abdominal cavities on igloo is put on freeend vicryl threads, And she together With with a needle is extracted from abdominal cavities (Drawing 23, 24). After overlays seam defect peritoneum is closing due in this way, themes the most is being eliminated risk exits internal organs outward.

Endoscopic knife For subtotal hysterectomies And morcellation. At laparoscopy still exist various

problems at dissections areas necks uterus, morcellations And extractions uterus And motoid nodes. Various techniques have been developed for morcellation. tools, But difficulties still enough, especially V cases When dimensions deleted fabrics great (myoma necks uterus, myoma big sizes). For solutions this problems De Grandi And other The co-authors developed an effective, sterilizable and cost-effective a profitable tool that allows for both cervical dissection uterus, as well as morcellation of the uterus or myoma. After dissection of the cervix uterus Maybe be removed With with help morcellator or cut with a knife Formorcellations And removed With with help vaginal CCL extractor.

Knife For morcellations consists of from ordinary blades No. 10, used V macrosurgery, which Maybe be replaced By desire. Blade is fastened To insert, which then connects With handle having retracting mechanism. This mechanism provides fully safe use, as the sharp blade is automatically retracted into external tube (rice. 6.9a and V).



Fig. 17. Morcellator Rotocut from company Karl Storz

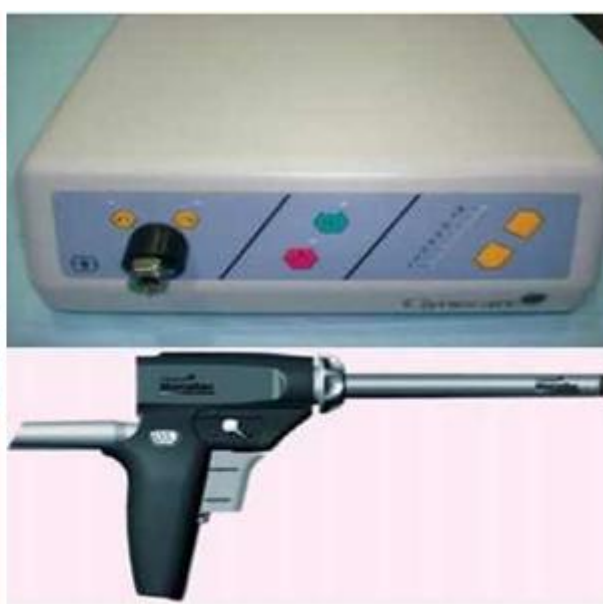

Fig. 18. Morcellator Gynaecare from companies Ethicon-Johnson and Johnson

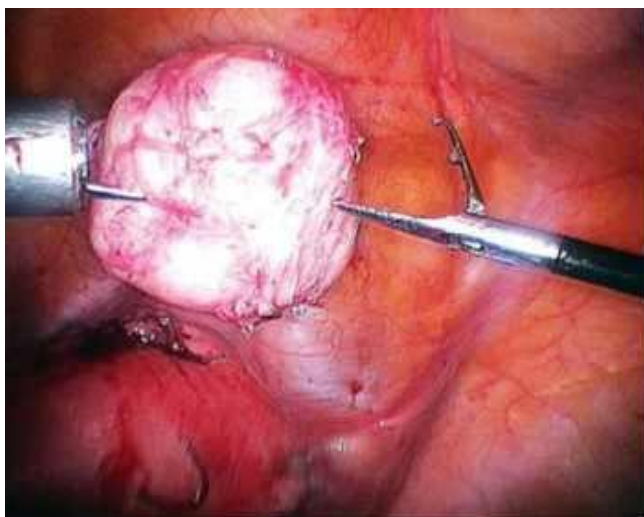


Fig. 19. Myoma is attracted closer to Cutting parts morcellator

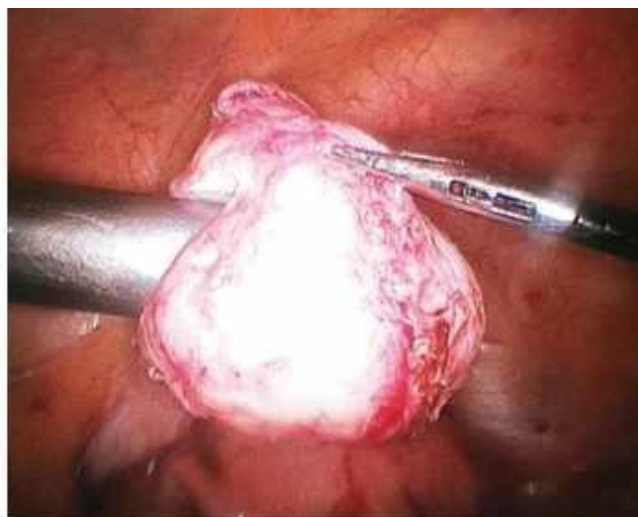

Fig. 20. The process of morcellation of the myoma

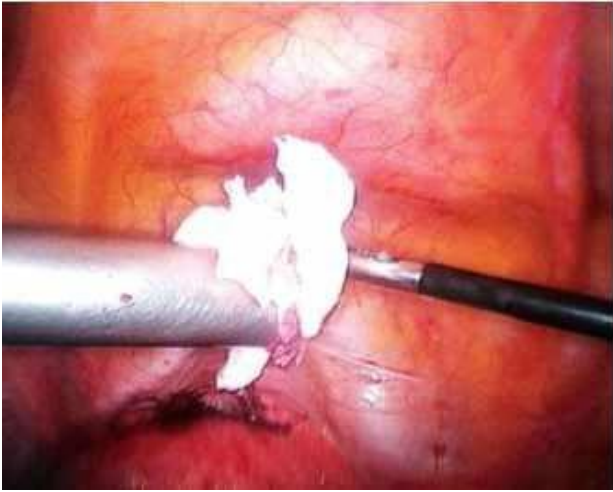


Fig. 21. Morcellation almost Completed

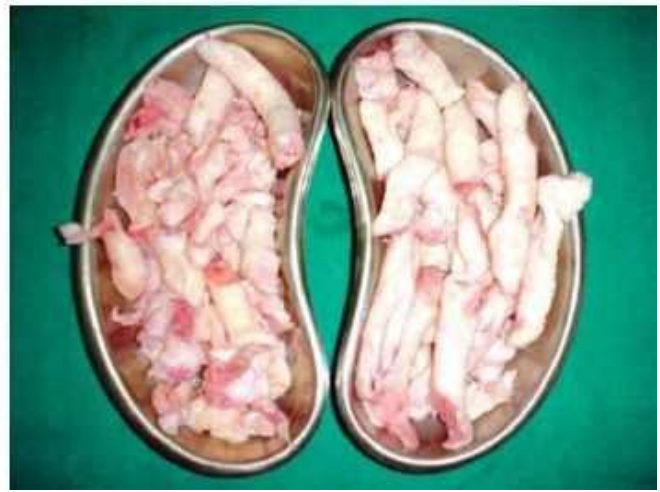

Fig. 22. View fabrics after morcellation



Fig. 23. Needle For closings defect peritoneum at laparoscopy

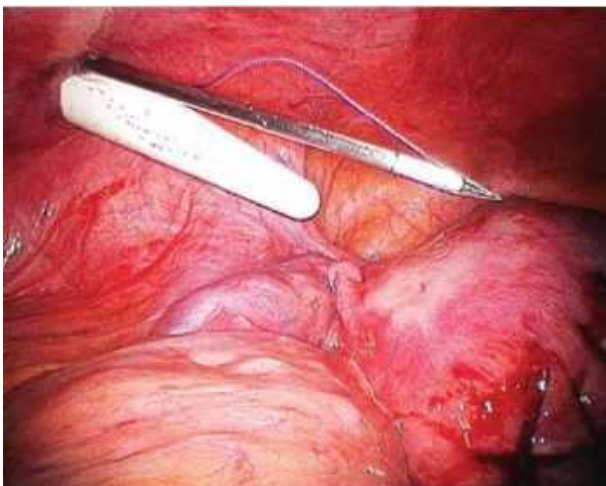
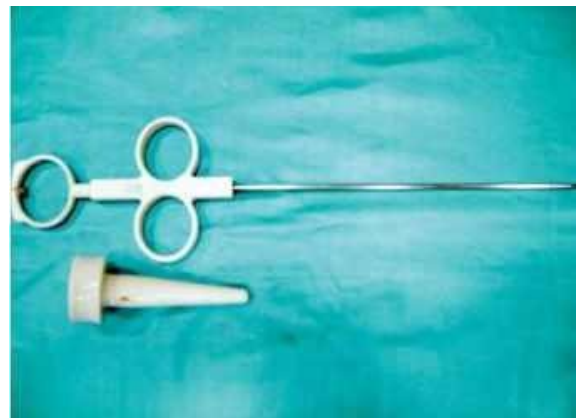


Fig. 24. Needle together With vicryl thread introduced V abdominal wound cavity

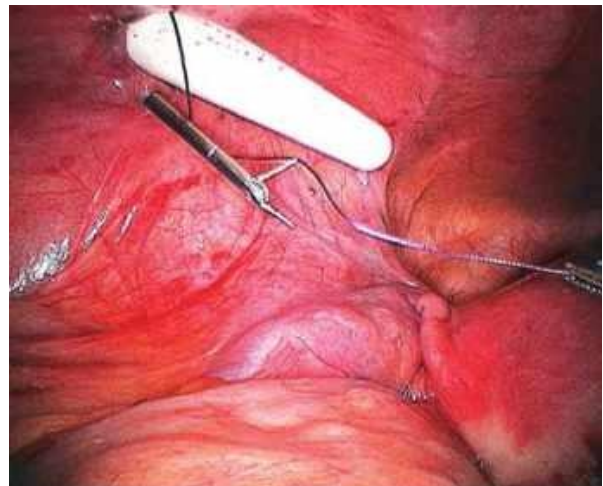


Fig. 25. The needle is inserted through the other edge is Free end threads is put on on needle

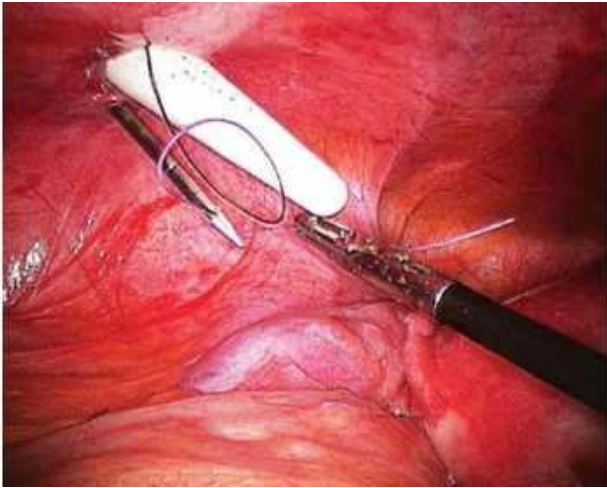


Fig. 26. Needle is extracted together with the vicryl thread

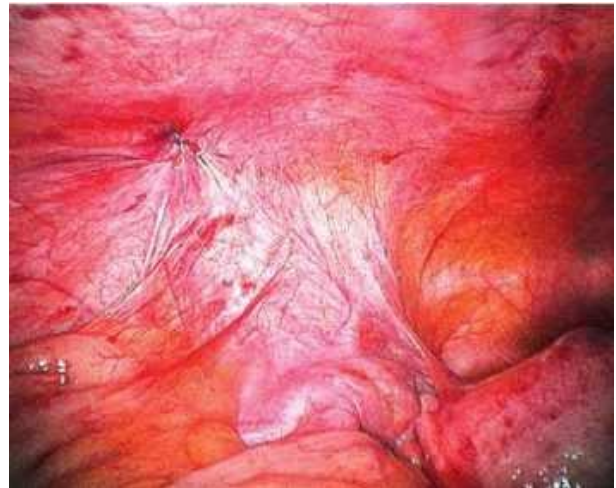

Fig. 27. Defect peritoneum liquidated. free the end of



Fig. 28. Laparoscopic tool EndoKnife For permissions fabrics



Literature:

1. Audebert AJ. Laparoscopic surgery of ovarian cyst. Current Opinions in Obstetrics and Gynecology. 1996;8:261-5.
2. Campo S, Garcea N. Laparoscopic conservative excision of ovarian dermoid cysts with and without an endobag. Journal of the American Association of Gynecologic Laparoscopists. 1998;5:165-70.
3. Steiner RA, Wight E, Tadir Y, et al. Electrical cutting device for laparoscopic removal of tissue from the abdominal cavity. Obstet Gynecol. 1993;81:471-4.
4. Carter JE, McCarus SD. Laparoscopic Myomectomy. Time and cost analysis of power vs. manual morcellation. J Reprod Med. 1997;42:383-8.
5. Kresch AJ, Lyons TL, Westland AB, et al. Laparoscopic supracervical hysterectomy with a new disposable Morcellator. J Am Assoc GynaecologyLaparosc. 1998;5:203-6.
6. Stringer HM, Walker JC, Meyer PM. Comparison of 49 laparoscopic myomectomies with 49 open myomectomies. J Am Assoc Gynecol Laparosc. 1997;4:457-64.

ОБЗОР РАЗЛИЧНЫХ МЕТОДОВ ЭКСТРАКЦИИ МАКРОПРЕПАРАТОВ ЛАПАРОСКОПИИ

Исломов Н.К., Мустафакулов И.Б., Жулбеков К.И.

Резюме. В настоящее время лапароскопические оперативные вмешательства прочно вошли в повседневную практику большинства лечебных учреждений. На основании комплексных рандомизированных исследований, проведённых во многих странах мира, были сформулированы основные преимущества лапароскопических операций по отношению к открытым способам выполнения аналогичных вмешательств, а именно меньшая степень выраженности болевых ощущений после операции, снижение расхода обезболивающих средств, более короткий срок пребывания в стационаре после операции, быстрое возвращение к привычной жизни и труду, хороший косметический эффект, низкая частота развития послеоперационных грыж.

Ключевые слова: Лапароскопия, мининвазивная, лапароскопическая хирургия, долихосигма.