



ISSN 2181-3388

ujcr.uz

eISSN 2181-3876

2024. Том 4. №3

# UZBEK JOURNAL OF CASE REPORTS

НАУЧНО-ТЕОРЕТИЧЕСКИЙ И ПРАКТИЧЕСКИЙ ЖУРНАЛ

МИРОВЫЕ НОВОСТИ

Дифференцированный подход при хирургическом  
лечении тяжелого острого панкреатита с  
прогнозированием результатов лечения



МИРОВЫЕ НОВОСТИ

Оценка клинических и лабораторных  
синдромов у гребцов на байдарках и каноэ

Google Scholar

НАУЧНАЯ ЭЛЕКТРОННАЯ  
БИБЛИОТЕКА  
**LIBRARY.RU**

**CYBERLENINKA**

**READera**

## Содержание

---

## Contents

---

- |  |    |  |
|--|----|--|
| Дифференцированный подход при хирургическом лечении тяжелого острого панкреатита с прогнозированием результатов лечения<br><i>Ризаев Э.А., Курбаниязов З.Б., Абдурахманов Д.Ш.</i> | 6  | Differentiated approach to surgical treatment of severe acute pancreatitis with prediction of treatment outcomes<br><i>Rizaev EA, Kurbaniyazov ZB, Abdurakhmanov DSh</i> |
| Оптимизация подвижности медиального мениска: персональный подход и артроскопическое восстановление<br><i>Маматкулов К.М., Абдусаматов Ш.Н., Холиккулов М.Т.</i>                    | 12 | Optimization of medial meniscus mobility: personalized approach and arthroscopic repair<br><i>Mamatkulov KM, Abdusamatov ShN, Kholikulov MT</i>                          |
| Оценка клинических и лабораторных синдромов у гребцов на байдарках и каноэ<br><i>Ризаев Ж.А., Хусаинбоев Ш.Д.</i>  | 16 | Evaluation of clinical and laboratory syndromes in kayak and canoe rowers<br><i>Rizaev JA, Khusainboev ShD</i>   |
| Тяжелый случай внебольничной пневмонии, осложненный острым респираторным дистресс-синдромом и сепсисом<br><i>Усманов Б.Ж.</i>  | 22 | Severe case of community-acquired pneumonia complicated by acute respiratory distress syndrome and sepsis<br><i>Usmanov BZh</i>  |
-

*Optimization of medial meniscus mobility: personalized approach and arthroscopic repair*Mamatkulov KM<sup>1</sup>, Abdusamatov ShN<sup>2</sup>, Kholikulov MT<sup>2</sup><sup>1</sup> Samarkand State Medical University, Samarkand, Uzbekistan<sup>2</sup> Samarkand Branch of the Republican Specialized Scientific Practical Medical Center for Traumatology and Orthopedics, Samarkand, Uzbekistan

Corresponding author: Komiljon M. Mamatkulov, komilm@mail.ru

## Abstract

Medial meniscus hypermobility is a common cause of pain and discomfort in the knee joint, particularly among athletes and active individuals. Despite extensive research on meniscal tears, hypermobility remains an underexplored issue. Arthroscopic techniques offer minimally invasive solutions, but there is still no clear treatment protocol for patients with this pathology. Objective: To evaluate the effectiveness of the «all-inside» arthroscopic method combined with a personalized approach for treating medial meniscus hypermobility and improving clinical outcomes in patients with different knee injuries. Methods: The study included 34 patients who underwent arthroscopic medial meniscus reconstruction using the «all-inside» technique from January 2021 to September 2023. Patients were divided into groups based on the presence or absence of anterior cruciate ligament (ACL) injuries. Clinical outcomes were assessed using the IKDC scale before and after surgery. Results: Patients showed significant improvements in subjective IKDC scores, from 54.11 to 84.56 ( $p < 0.005$ ). In 85% of cases, only one segment of the meniscus was affected, enabling successful repair without further interventions. The main complications were restricted joint mobility and prolonged pain syndrome in a few patients. Conclusion: The arthroscopic method for treating medial meniscus hypermobility with a personalized approach demonstrated high clinical efficacy. However, further research is needed to identify factors influencing outcomes to minimize complications.

Keywords: medial meniscus hypermobility, arthroscopy, meniscus reconstruction, anterior cruciate ligament, personalized approach.

For citation: Mamatkulov KM, Abdusamatov ShN, Kholikulov MT. Optimization of medial meniscus mobility: personalized approach and arthroscopic repair. Uzbek journal of case reports. 2024; 4(3):12-15. <https://doi.org/10.55620/ujcr.4.3.2024.2>

*Оптимизация подвижности медиального мениска: персональный подход и артроскопическое восстановление*Маматкулов К.М.<sup>1</sup>, Абдусаматов Ш.Н.<sup>2</sup>, Холикулов М.Т.<sup>2</sup><sup>1</sup> Самаркандский государственный медицинский университет, Самарканд, Узбекистан<sup>2</sup> Самаркандский филиал Республиканского специализированного научно-практического медицинского центра травматологии и ортопедии, Самарканд, Узбекистан

Автор, ответственный за переписку: Маматкулов Комилжон Марданкулович, komilm@mail.ru

## Аннотация.

Гипермобильность медиального мениска является частой причиной болевого синдрома и дискомфорта в коленном суставе, особенно у спортсменов и лиц, ведущих активный образ жизни. Несмотря на значительное количество исследований, касающихся лечения разрывов мениска, гипермобильность остаётся недостаточно изученной проблемой. Артроскопические методы лечения предлагают минимально инвазивные решения, но до сих пор отсутствует чёткий алгоритм лечения пациентов с данной патологией. Цель исследования: Оценить эффективность артроскопического метода «all-inside» в сочетании с персонализированным подходом для лечения гипермобильности медиального мениска и улучшения клинических результатов у пациентов с разными типами повреждений коленного сустава. Методы: В исследование включены 34 пациента, которым была выполнена артроскопическая реконструкция медиального мениска с использованием техники «all-inside» с января 2021 по сентябрь 2023 года. Пациенты были разделены на группы в зависимости от наличия или отсутствия повреждения передней крестообразной связки. Клинические результаты оценивались с использованием шкалы IKDC до и после хирургического вмешательства. Результаты: Пациенты показали значительное улучшение субъективных показателей по шкале IKDC: от 54,11 до 84,56 ( $p < 0,005$ ). В 85% случаев поражение касалось только одного сегмента мениска, что позволило выполнить успешное восстановление без повторных вмешательств. Основными осложнениями были ограничение подвижности сустава и длительный болевой синдром у нескольких пациентов. Заключение: Артроскопический метод лечения гипермобильности медиального мениска с персонализированным подходом показал высокую клиническую эффективность. Однако требуется дальнейшее исследование факторов, влияющих на исходы, для снижения риска осложнений.

Ключевые слова: гипермобильность медиального мениска, артроскопия, реконструкция мениска, передняя крестообразная связка, персонализированный подход.

Для цитирования: Маматкулов К.М., Абдусаматов Ш.Н., Холикулов М.Т. Оптимизация подвижности медиального мениска: персональный подход и артроскопическое восстановление. Uzbek journal of case reports. 2024; 4(3):12-15. <https://doi.org/10.55620/ujcr.4.3.2024.2>

**Introduction.** In the present literature, there is limited attention to the treatment of hypermobility of the medial meniscus, in clear contrast to the more frequently mentioned hypermobility of the lateral meniscus. Despite its frequent manifestation, the diagnosis of this problem turns out to be poorly illuminated in existing literary sources. We focus on the pathology associated with hypermobility of the medial meniscus, which in most cases is associated with a violation of the integrity of the paracapsular or peripheral zone of the meniscus. Our article draws attention to the paracapsular lesions of the medial meniscus, which are often assessed as favorable in terms of subsequent scarring, but at the same time, as our experience shows, they do not always pass without a trace for the patient. Insufficient diagnosis of such injuries is often accompanied by clinical symptoms that significantly affect the quality of life of patients.

The purpose of our comprehensive study is to identify effective methods of treatment and rehabilitation of patients

with hypermobility of the medial meniscus due to various causes, including long-standing paracapsular lesions. We strive not only to evaluate the results of meniscocapsular sutures and the «everything inside» method in the treatment of this problem, but also to identify key prognostic factors such as epidemiological, clinical and operational aspects that affect the success of surgical interventions and meniscus repair. Our common goal is to provide a comprehensive view of the treatment of medial meniscus hypermobility, which can become the basis for optimizing clinical practice and improving outcomes in the treatment of this condition.

**Materials and methods:** The study was conducted between January 2021 and September 2023. The observation group consisted of 34 patients who underwent arthroscopic reconstruction of the meniscus using the «everything inside» technique. Inclusion in the group was carried out subject to the following criteria: absence of pronounced degenerative changes in the meniscus, rehabilitation procedures in red-

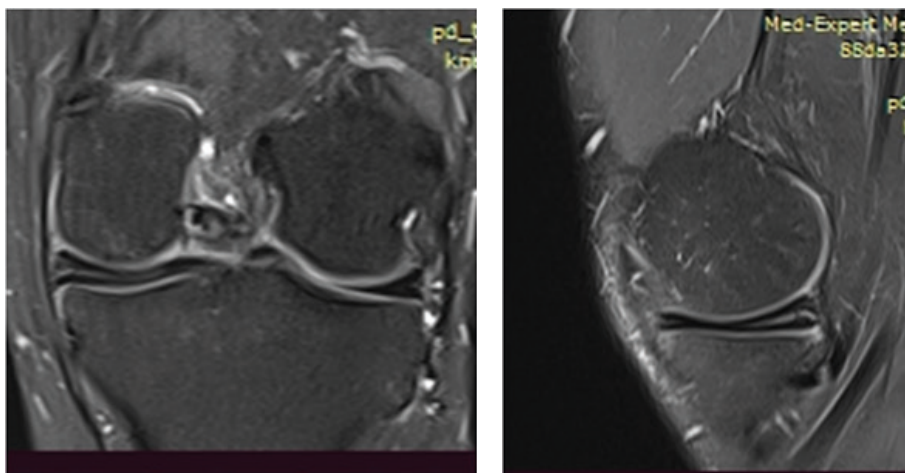


Figure 1.

MRI image of radial damage to the medial meniscus.

red and red-white zones, surgery within three months from the moment of injury, age from 20 to 40 years in 24 patients, and over 40 years in 10 patients. Reconstruction was carried out both in case of rupture of the anterior cruciate ligament and without it.

The exclusion criteria included 8 cases of radial meniscus injury (Fig.1), 16 cases of meniscus rupture of the «watering can handle» type (Fig.2), previous knee surgery and 4 cases of degenerative meniscus injury.

The total number of patients was 34, including 12 women and 22 men, with an average age of 26 years (20-40 years). The study covered 16 cases of right knee injury and 18 cases of left knee injury. Hypermobility of the medial meniscus was 38% (13 cases), of the lateral meniscus — 62% (21 cases). There were no cases of simultaneous suturing of both menisci.

In 85% of cases (30 people), only one segment of the meniscus was affected, in 15% of cases (4 people) — two. The meniscus suture was not used in cases of widespread ruptures (more than two segments), such cases were considered as prognostically unfavorable. In 30% of cases, operations (10 people) were performed with an intact anterior cruciate ligament (ACL), in 70% of cases (24 people), the ACL was damaged and its reconstruction was carried out simultaneously with the meniscal suture.

The average interval between injury and surgery was 56 days (22-81 days). Meniscus repair was performed arthroscopically under control using Fast-Fix 360® (Smith&Nephew) and Omnispan (DePuy Mitek) systems. The average number of stitches is 2 per damage segment. The rupture was treated with a shaver and a rasp hook to remove scar tissue in order to accelerate healing.

Data collected before, during and after surgery were used to analyze prognostic factors. In case of failure, understood as the need for revision arthroscopy with subtotal removal of the same meniscus after a positive result of an MRI examination, revision surgery was performed.

The subjective and objective parameters of the IKDC (International Knee Documentation Committee) scale were measured before and after surgery.

**The results and their discussions.**

The average follow-up period was up to 2 years. During this time, there was no need for revision arthroscopic interventions to re-suture the meniscus or meniscectomy. Subjective indicators measured on the IKDC scale improved significantly from 54.11 to 84.56 ( $p < 0.005$ ), emphasizing the positive effect of surgical intervention.

Complications identified as a result of the study included limited mobility of the knee joint with the development

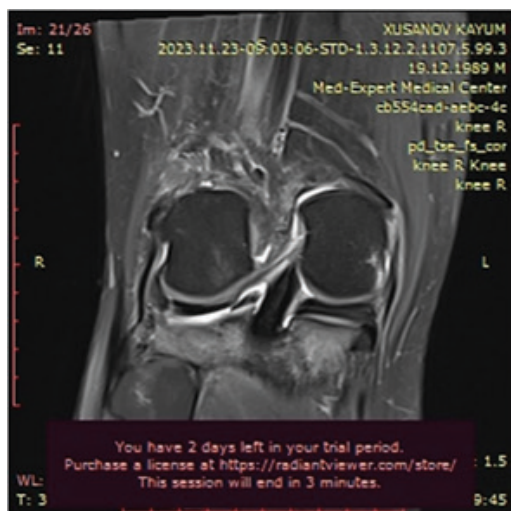

Figure 2.

MRI drawing of a rupture of the lateral meniscus according to the type of "watering can handle"

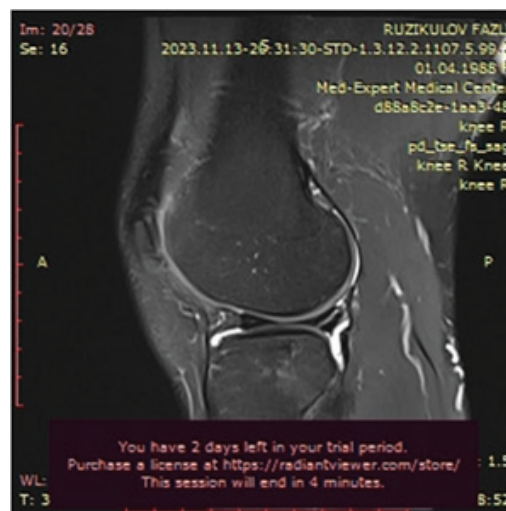

Figure 3.

MRI image pattern of horizontal rupture of the medial meniscus.

of moderate extensor contracture in two cases associated with suturing of the medial meniscus, and long-term pain syndrome in one case associated with suturing of the lateral meniscus. Neurovascular complications or migration of the implant were not recorded.

It was noted that overweight patients were carefully selected for surgery due to the alleged effect of a high body mass index on the recovery process. With a BMI of more than 35 (grade 2 and 3 obesity), meniscus resection or meniscectomy was used.

The results of our study demonstrate the long-term effectiveness of arthroscopic meniscus repair using the «everything inside» technique in the treatment of hypermobility of the medial and lateral meniscus. The absence of the need for audit operations indicates the stability of the result during the three-year observation period.

The obtained improvements in subjective assessments on the IKDC scale confirm the success of rehabilitation procedures and a positive impact on the quality of life of patients. However, the identified complications, such as limited mobility and pain syndrome, emphasize the need for further study of the factors influencing the results of surgery.

The approach to overweight patients and the preference for meniscus resection in the case of high BMI emphasize the importance of individualizing surgical intervention depending on the characteristics of patients.

In conclusion, our results support the effectiveness of arthroscopic meniscus repair and warn against possible complications that require additional attention when planning and conducting operations.

#### REFERENCES.

1. Faizan A, Goldstein J, Edelman S, et al. Comparison of post-operative knee stability and return to sports outcomes between all-inside and transportal ACLR. *Sports Health*. 2020;12(2):184-190. doi:10.1177/1941738119875243.
2. Foster BD, Munns C, Smith BT, et al. All-inside versus transportal ACL reconstruction: a meta-analysis of patient-reported outcomes and complications. *Am J Sports Med*. 2021;49(1):144-150. doi:10.1177/0363546520949391.
3. Gualtieri D, Monaco E, De Carli A, et al. Long-term clinical and radiographic results after all-inside ACL reconstruction. *J Knee Surg*. 2021;34(4):329-337. doi:10.1055/s-0039-1700882.
4. Hamill J, Murphy I, Whelan D, et al. The clinical efficacy of transportal and all-inside ACL reconstruction: a meta-analysis. *BMC Musculoskelet Disord*. 2021;22:267. doi:10.1186/s12891-021-04122-0.
5. Hewison C, England A, Haskell A. All-inside ACL reconstruction technique: patient outcomes and complications. *Orthop J Sports Med*. 2020;8(2):3235. doi:10.1177/2325967119896942.
6. Karimov MY, Tolochko KP, Mamatkulov KM. Anterior knee pain syndrome. *J Adv Med Med Res*. 2019;30(3):1-8. doi:10.9734/JAMMR/2019/v30i330178.
7. Karimov MY, Tolochko KP, Mamatkulov KM. Anterior knee pain syndrome. *Vestnik Tashkentskoi Meditsinskoi Akademii*. 2017;(5):9-13. (In Russ.)
8. Karimov MY, Tolochko KP, Mamatkulov KM. Kujala questionnaire for patients with anterior knee pain. *Uzbek Tibbiyot Zhurnali*. 2019;(2):111-113. (In Russ.)
9. Kim SH, Lee SH, Kim JH, et al. Minimally invasive all-inside ACL reconstruction technique: a comparative study of patient outcomes. *J Korean Orthop Assoc*. 2020;55(2):101-107. doi:10.4055/jkoa.2020.55.2.101.
10. Kouloumentas P, Kouloumentas P, Papadopoulos G, et al. Long-term outcomes of all-inside versus full tibial tunnel ACL reconstruction. *Arthroscopy*. 2021;37(1):45-53. doi:10.1016/j.arthro.2020.06.039.
11. Koutras G, Papavasileiou X, Tsagkozis P, et al. Systematic review comparing the outcomes of ACL reconstruction using transportal and all-inside techniques. *Clin Orthop Relat Res*. 2021;79(9):2055-2064. doi:10.1097/01.blo.0000717856.65871.6d.
12. Kraus T, Heidari N, Švehlík M, Schneider F, Sperl M, Linhart W. Outcome of repaired unstable meniscal tears in children and adolescents. *Acta Orthop*. 2012;83(3):261-266.
13. Lemanek NJ, Huber K, Fraga J, et al. Patient satisfaction after all-inside ACL reconstruction: A two-year follow-up. *Clin J Sport Med*. 2021;31(1)
14. Lu G, Li X, Zhang J, et al. Arthroscopic all-inside versus conventional ACL reconstruction: a prospective comparative study. *BMC Musculoskelet Disord*. 2021;22:555. doi:10.1186/s12891-021-04232-7.
15. Lv Y, Qiu J, Wang J, et al. Is all-inside with suspensory cortical button fixation a superior technique for anterior cruciate ligament reconstruction surgery? A systematic review and meta-analysis. *BMC Musculoskelet Disord*. 2020;21:450. doi:10.1186/s12891-020-03352-4.
16. Lyle NJ, Sampson MA, Barrett DS. MRI of intermittent meniscal dislocation in the knee. *Br J Radiol*. 2009;82:374-379.
17. Mahmud MR, Karim MB, Rahman MS. Comparison of surgical outcomes between all-inside and full tibial tunnel techniques in ACL reconstruction. *Arch Orthop Trauma Surg*. 2020;140(5):673-680. doi:10.1007/s00402-020-03342-1.
18. Mamatkulov K, Kholkhudjayev F, et al. Our experience of plastic surgery of the anterior cruciate ligament using the «All Inside» method with the tendons of the popliteal flexors or the tendon of the long fibular muscle. *Pol J Sci*. 2021;45(1):42-44.
19. Mamatkulov KM, Xolxo'jayev FI, Rakhmonov SH. Reconstruction of the anterior cruciate ligament with popliteal flexor tendons or the tendon of the long fibular muscle. *Zhurnal Akademicheskikh Issledovaniy i Nauk*. 2021;2(2):1214-1219. doi:10.24411/2181-1385-2021-00326. (In Russ.)
20. Mamatkulov KM, Xolxo'jayev FI. Arthroscopic restoration of the anterior cruciate ligament using the «All Inside» method with popliteal flexor tendons or long fibular muscle tendon. *Problemy Biologii i Meditsiny*. 2023. (In Russ.)
21. Monaco E, Fabbri M, Redler A, et al. All-inside technique for ACL reconstruction with augmentation: long-term follow-up. *J Knee Surg*. 2021;34(3):210-217. doi:10.1055/s-0039-1694010.
22. Monaco E, Redler A, De Carli A, et al. Long-term outcomes of anterior cruciate ligament reconstruction using the all-inside technique. *J Orthop Sports Phys Ther*. 2020;50(8):374-380. doi:10.2519/jospt.2020.9367.
23. Morrison JB, Tuck KL, Lee J, et al. Comparative outcomes of all-inside versus conventional ACL reconstruction: a multicenter randomized controlled trial. *Arthroscopy*. 2020;36(7):1938-1946. doi:10.1016/j.arthro.2020.02.029.
24. Muaidi QI, Hegazy FA, Ahmed AF, et al. Effect of all-inside anterior cruciate ligament reconstruction on postoperative outcomes. *Saudi J Sports Med*. 2021;9(2):152-160. doi:10.4103/sjms.sjms\_79\_20.

25. Orr R, Fox A, Hughson RL, et al. Transportal versus all-inside ACL reconstruction: a comparative study of biomechanical and functional outcomes. *J Orthop Surg Res.* 2021;16:87. doi:10.1186/s13018-020-02135-8.
26. Pace V, Adams RD, Tofts L, Munns CF, Nicholson LL. Proprioceptive acuity into knee hypermobile range in children with joint hypermobility syndrome. *Pediatr Rheumatol.* 2014;12:408.
27. Park YB, Ha JK, Kim SW, et al. Biomechanical comparison between transportal and all-inside techniques in ACL reconstruction. *Clin Orthop Surg.* 2020;12(3):352-360. doi:10.4055/cios2020.12.3.352.
28. Song EK, Kim SK, Yoo JH, et al. All-inside technique versus conventional ACL reconstruction with a hamstring autograft: A retrospective comparative study. *Knee Surg Sports Traumatol Arthrosc.* 2020;28(2):502-509. doi:10.1007/s00167-019-05589-0.
29. Söylev S, Pınar İH. Results of meniscus repair for the hypermobile medial meniscus. Dokuz Eylül Univ, Dep Orthop Traumatol, Izmir, Turkey; Ata Sağlık Hospital, Clinic of Orthopaedics and Traumatology, Izmir, Turkey.
30. Thomeé R, Karlsson J, Holmgren K, et al. Functional outcomes and return to sport after all-inside ACL reconstruction. *Orthop J Sports Med.* 2020;8(5):253. doi:10.1177/2325967119900814.

Received 20.06.2024; reviewed 25.08.2024; accepted for publication 23.09.2024.

*Author information:*

Komiljon M. Mamatkulov — PhD, Assistant of the Department of Traumatology and Orthopedics, Samarkand State Medical University, Samarkand, Uzbekistan.

Shahridin N. Abdusamatov — Resident Doctor, Samarkand Branch of the Republican Specialized Scientific Practical Medical Center for Traumatology and Orthopedics, Samarkand, Uzbekistan.

Mirobid T. Kholikulov — Clinical Resident, Samarkand Branch of the Republican Specialized Scientific Practical Medical Center for Traumatology and Orthopedics, Samarkand, Uzbekistan.

Authors' contribution: Mamatkulov KM — concept and design of the study, manuscript writing; Abdusamatov ShN — data collection, data analysis; Kholikulov MT — data collection, manuscript editing.

Funding: The work had no specific funding.

Conflict of interest: The authors declare no explicit and potential conflicts of interest associated with the publication of this article.

Статья поступила 20.06.2024; одобрена после рецензирования 25.08.2024; принята к публикации 23.09.2024.

*Информация об авторах:*

Маматкулов Комилжон Марданкулович — к.м.н., ассистент кафедры травматологии и ортопедии, Самаркандский государственный медицинский университет, Самарканд, Узбекистан.

Абдусаматов Шахриддин Нуриддин угли — врач ординатор, Самаркандский филиал Республиканского научно-практического медицинского центра травматологии и ортопедии, Самарканд, Узбекистан.

Холикулов Миробид Тургунбаевич — клинический ординатор, Самаркандский филиал Республиканского научно-практического медицинского центра травматологии и ортопедии, Самарканд, Узбекистан.

Вклад авторов: Маматкулов К.М. — концепция и дизайн исследования, написание текста рукописи; Абдусаматов Ш.Н. — сбор данных, анализ полученных данных; Холикулов М.Т. — сбор данных, редактирование текста.

Источники финансирования: Работа не имела специального финансирования.

Конфликт интересов: Авторы декларируют отсутствие явных и потенциальных конфликтов интересов, связанных с публикацией настоящей статьи.