



UJCR

ISSN 2181-3388

ujcr.uz

eISSN 2181-3876

2024. Том 4. №2

# UZBEK JOURNAL OF CASE REPORTS

НАУЧНО-ТЕОРЕТИЧЕСКИЙ И ПРАКТИЧЕСКИЙ ЖУРНАЛ

МИРОВЫЕ НОВОСТИ

Влияние гиперкифоза шейного отдела  
позвоночника на развитие головной боли



СЛУЧАЙ ИЗ ПРАКТИКИ

Летальный случай ранения свето-шумовой  
гранатой в грудь

Google Scholar

НАУЧНАЯ ЭЛЕКТРОННАЯ  
БИБЛИОТЕКА  
**LIBRARY.RU**

CYBERLENINKA

READera

## Содержание

## Contents

Симптоматика, этиология и виды лечения травм повреждений плечевого сустава (литературный обзор) <i>Хусаинбоев Ш.Д.</i>	6	Symptomatology, etiology, and treatment types for shoulder joint injuries (literature review) <i>Khusainboev ShD</i>
Возможности миниинвазивных вмешательств при лечении больных асептическим тяжелым панкреатитом <i>Ризаев Э.А., Курбаниязов З.Б., Абдурахманов Д.Ш.</i>	10	Minimally invasive intervention possibilities in the treatment of patients with severe aseptic pancreatitis <i>Rizaev EA, Kurbaniyazov ZB, Abdurakhmanov DSh</i>
Влияние гиперкифоза шейного отдела позвоночника на развитие головной боли <i>Ризаев Ж.А., Хакимова С.З., Гулямова Г.А., Муродов А.Г.</i>	14	The effect of cervical hyperkyphosis on the development of headache <i>Rizaev JA, Hakimova SZ, Gulyamova GA, Murodov AG</i>
Влияние стресса на эффективность комплексного лечения заболеваний пародонта у преподавателей и школьных учителей <i>Ризаев Ж.А., Кундузов О.Ш., Хазратов А.И., Ражабий М.А.</i>	20	The effect of stress on the efficacy of comprehensive periodontal disease treatment in teachers and school instructors <i>Rizaev JA, Kunduzov Osh, Khazratov AI, Rajabiy MA</i>
Летальный случай ранения свето-шумовой гранатой в грудь (клинический случай) <i>Усманов Б.Ж.</i>	27	Fatal case of chest injury from a flash-bang grenade (clinical case) <i>Usmanov BZh</i>

*Fatal case of chest injury from a flash-bang grenade (clinical case)*

Usmanov BZh

Thoracic Surgery Department, Central Military Clinical Hospital, Ministry of Defense, Republic of Uzbekistan, Tashkent

*Corresponding author:* Babur Zh. Usmanov, [usmbabur@gmail.com](mailto:usmbabur@gmail.com)**Abstract**

Flash-bang grenades are classified as non-lethal weapons, used to temporarily incapacitate the enemy. However, they can cause severe injuries if detonated in close proximity to an individual. This article presents a clinical case of a severe chest injury caused by the explosion of a flash-bang grenade. Objective: To describe a clinical case and highlight the key tactical approaches to treating such injuries. Methods: The patient was admitted with a severe gunshot wound in the II-III rib projection. Emergency surgery was performed to remove the grenade body and drain the pleural cavity. Postoperatively, the patient was transferred to the intensive care unit for intensive therapy, including antibacterial treatment, infusions, and bronchoscopy. Results: Despite the interventions, the patient developed complications, including necrotic changes in soft tissues and recurrent hemorrhages. The patient died on the 11th day post-injury from acute blood loss. Conclusion: Injuries caused by flash-bang grenade explosions require thorough diagnostics and a tailored approach to treatment. It is crucial to consider the complexity of thermal and mechanical damage when choosing the surgical tactics.

*Keywords:* Flash-bang grenade, gunshot wounds, chest injuries, thoracotomy, pleural drainage, tissue necrosis

For citation: Usmanov BZh. Fatal case of chest injury from a flash-bang grenade. Uzbek journal of case reports. 2024; 4(2):27-30. <https://doi.org/10.55620/ujcr.4.2.2024.5>

*Летальный случай ранения свето-шумовой гранатой в грудь (клинический случай)*

Усманов Б.Ж.

Центральный военный клинический госпиталь Министерства Обороны Республики Узбекистан, Ташкент

*Автор, ответственный за переписку:* Усманов Бабур Женисбай улы, [usmbabur@gmail.com](mailto:usmbabur@gmail.com)**Аннотация.**

Свето-шумовые гранаты классифицируются как нелетальные средства, используемые для временного обездвиживания противника. Однако они могут вызывать серьезные повреждения, если взрываются в непосредственной близости от человека. В данной статье представлен клинический случай тяжелого ранения грудной клетки, вызванного взрывом свето-шумовой гранаты. Цель исследования: Описать клинический случай и выделить основные тактические подходы к лечению таких ранений. Методы: Пациент поступил с тяжелым огнестрельным ранением в проекции II-III ребер. Выполнена экстренная операция с удалением тела гранаты и дренированием плевральной полости. После операции пациент был переведен в реанимационное отделение для интенсивной терапии, включающей антибактериальную терапию, инфузии и бронхоскопию. Результаты: Несмотря на проведенные мероприятия, у пациента развились осложнения, включая некротические изменения в мягких тканях и повторные кровотечения. Пациент умер на 11-е сутки после травмы от острой кровопотери. Заключение: Случаи ранений, вызванных взрывами свето-шумовых гранат, требуют тщательной диагностики и индивидуализированного подхода к лечению. Важно учитывать сложность термических и механических повреждений при выборе тактики хирургического вмешательства.

*Ключевые слова:* Свето-шумовая граната, огнестрельные ранения, раны грудной клетки, торакотомия, плевральный дренаж, некроз тканей

Для цитирования: Усманов Б.Ж. Летальный случай ранения свето-шумовой гранатой в грудь. Uzbek journal of case reports. 2024; 4(2):27-30. <https://doi.org/10.55620/ujcr.4.2.2024.5>

**INTRODUCTION**

In order to combat crime and protect public order, as well as ensure public safety, law enforcement officers use special means, some of which are classified as non-lethal weapons. One of these special means is shots of light and sound effect and a delivery vehicle in the form of a hand grenade launcher. In this article we present a clinical case of a chest wound from a flash-noise grenade. These special means are used to temporarily stun and immobilize enemy forces located in close proximity by producing loud, temporarily paralyzing noise and a blinding flash.

Gunshot wounds to the chest are characterized by high mortality. Based on data from recent local conflicts and wars, the incidence of breast injuries ranges from 11.7% to 22.7% [1,2,3]. The severity of the condition of those wounded in the chest is determined by damage to vital organs, the amount of blood loss, and the development of shock. In such cases, timely and correct provision of qualified and specialized surgical care is necessary.

A systematic clinical examination, including examination, palpation, percussion, auscultation, study of the nature and location of wounds, etc., is essential in assessing the condition of the victim, even in emergency care, etc. On this basis and in the absence of other research methods, it is often possible to determine the type of penetrating wound. chest wounds and take immediate medical measures [4]. The use

of instrumental diagnostic methods plays an important role in determining the choice of treatment tactics. The role of plain radiography and ultrasound (US) in chest trauma is generally accepted. Computed tomography (CT) for chest wounds is currently a highly informative diagnostic method.

With penetrating chest wounds, the mortality rate ranges from 10 to 50%, with non-penetrating wounds it does not exceed 1%. Intrapleural bleeding in 87.5% of those who died at the stage of qualified medical care occurred due to damage to the peripheral part of the lung, and in 8.3% from the central part, without damage to large vessels [5]. Determining the level of activity when providing emergency surgical care for penetrating chest wounds is far from easy [6]. Thoracotomy for gunshot wounds of the chest is the main, but not always necessary, surgical procedure. Installation of pleural drainage plays a dominant role in the diagnosis and initial treatment measures for penetrating gunshot wounds of the chest. Up to 85% of wounded patients require this minimally invasive procedure [6]. Thoracentesis and drainage of the pleural cavity was the main method in the treatment of penetrating gunshot wounds of the chest; it was used in 258 (80.1%) wounded [7]. For gunshot wounds to the chest among British military personnel in Iraq and Afghanistan, in 66% of cases, treatment measures were limited to drainage of the pleural cavity [8]. In the I.P. Khomenko et al. (2018) research with combat chest injuries, 39.8% of the wounded



needed only pleural drainage [9]. In contrast, Voskresensky O.V. (2015) leads that the 18.4% of patients with penetrating chest wounds required only drainage [10].

#### CASE REPORT

Patient T., 25 years old, was wounded on the left side of the chest by a grenade and was taken to the emergency department of one of the branches of the Republican Research Center of Emergency Medicine 20 minutes after the injury. Upon admission, the general condition was severe, consciousness was stunned, the skin was pale, blood pressure (BP) on admission was 90/60 mm Hg, pulse was rapid 110 beats per minute. Upon objective examination, on the left half of the chest, in the projection of the II-III ribs, there is an entrance gunshot wound, measuring 5.0x2.0 cm. With a preliminary diagnosis of "Gunshot penetrating wound of the chest on the left, hemopneumothorax on the left, traumatic shock II," he was taken to the operating room. Laboratory parameters upon admission: general blood test: hemoglobin 129.0 g/l, erythrocytes  $3.9 \times 10^{12}/l$ , leukocytes  $6.8 \times 10^9/l$ ; biochemical blood test: glucose 6.0 mmol/l, total protein 72.1 g/l, urea 7.0 mmol/l, creatinine 71.2 mmol/l, ALT 44.5 IU/l, AST 40.2 IU/l, a-amylase 13.5 U/l.

The left pleural cavity was opened by a left-sided lateral thoracotomy; during revision of the pleural cavity, in the parenchyma of the left upper lobe there was a grenade body measuring 10.0x5.0 cm (Fig. 1). The grenade body was removed (foreign body 1), air was coming from the wound, the edges of the wound were black, the pulmonary parenchyma was airless. The edges of the wound are excised, the lung wound is sutured with interrupted sutures. The left pleural cavity was washed with saline and drained with 0.5 cm diameter drainage and the surgical wound was sutured in layers.

The patient was transferred from the operating room to the intensive care unit, breathing through a mechanical ventilation, SpO<sub>2</sub> 92%, blood pressure was 100/60 mm Hg, pulse 110-120/min, body temperature 36.70C. In intensive therapy was carried out: antibacterial, infusion, blood transfusion, symptomatic. On a postoperative control chest X-ray after 2 hours: left-sided hydropneumothorax. After control examination chest drain was performed in the 2nd intercostal space along the left midclavicular line, above the entrance

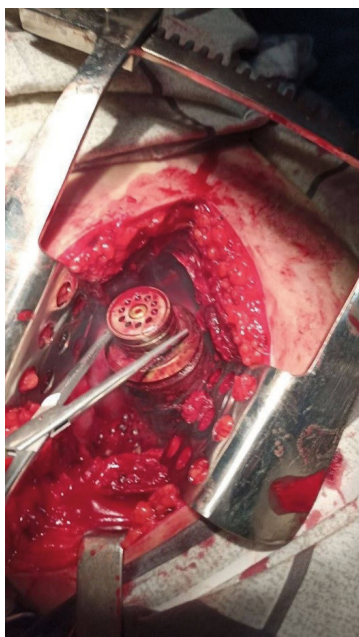


Fig.1.

Grenade body in the left upper lobe.

gunshot wound. The patient was extubated on the first postoperative day, his general condition remained severe, he was conscious, and complained of pain in the left side of the chest and weakness. He was breathing independently, supplying humidified oxygen through a mask, percussion on the left was a box sound, auscultation in the lungs was harsh breathing, sharply weakened on the left. Hemodynamic parameters: blood pressure 100/60, pulse 125-130 per minute, rapid, heart sounds muffled. The drainage shows serous-hemorrhagic discharge. The control ultrasound of the pleural cavities did not reveal any fluid in the left pleural cavity; echocardiography could not be performed due to severe subcutaneous emphysema and persistent lung collapse. Due to psychomotor agitation, the patient was sedated. On the second day after the operation, a sanitary bronchoscopy was performed, which revealed obstruction of the left lower lobe bronchus with a blood clot.

On the second postoperative day, the patient was evacuated by air transport to the Central Military Clinical Hospital of the Ministry of Defense of the Republic of Uzbekistan. Upon arrival at the hospital, he was examined and objectively there was a sutured entrance wound on the left half of the chest; drains with a diameter of 0.5 cm were installed above the wound in the 2nd intercostal space along the midclavicular line and the posterior axillary line; on the left half of the chest and the left lateral quadrant of the abdominal wall subcutaneous emphysema was noted. A control CT scan of the chest was performed, which showed a foreign body in the soft tissues of the left half of the chest, measuring 2.5x4.5x3.0 cm (Fig. 2 and 3), pneumothorax, contusion of the left lung, fracture of ribs 3-4 along the anterior segments, 6 along the rear segment on the left; CT scan of the brain shows multiple zones of diffuse decrease in the density of the brain matter in the right parieto-occipital and right hemisphere of the cerebellum.

Foreign body 2 (Fig. 4) was removed from the soft tissues of the left half of the chest under general anesthesia on fourth postoperative day. The foreign body turned out to be the fuse, which is usually located at the head of the grenade. Foreign body 2 crushed the 6th rib and the corner of the left scapula. The edges of the ribs were processed with nippers, the foreign body bed communicated with the pleural cavity. The tissues immediately adjacent to foreign body 2 were necrotic, the muscles looked like boiled meat. All non-viable tissues were excised, the wound was packed with gauze pads soaked in levomekol ointment.

Four interrupted sutures applied to the skin of the entrance wound showed signs of failure. The sutures were released and an inspection was carried out, during which the following was discovered: all the underlying tissue, or rather the subcutaneous tissue, muscles (pectoralis major and minor, intercostal muscles) remained untreated. The color of the tissues was black, exuding a specific mixed smell of burnt meat with carbon monoxide; after excision, under these necrotic tissues there were muscles that looked like boiled meat. All non-viable tissues were excised, as a result the fragmented edges of 3-4 ribs were exposed, the sharp edges were bitten off using Liston nippers. As a result of treatment and excision of the entrance wound of the left half of the chest, a skin defect with a diameter of 7 cm was formed, a muscle layer of the anterior wall of the left half of the chest with a diameter of about 20-22 cm. Since it was not possible to seal the chest wall, due to the inflamed tissues, an occlusive five-layer bandage (according to Banaitis), instead of Vaseline, gauze swabs were generously soaked in levomekol ointment. Drains with a diameter of 0.5 cm were replaced with silicone drains with a diameter of 1 cm. Drains with passive drainage.

In the postoperative period, the patient was in the intensive care unit, on artificial ventilation through a tracheal tube.

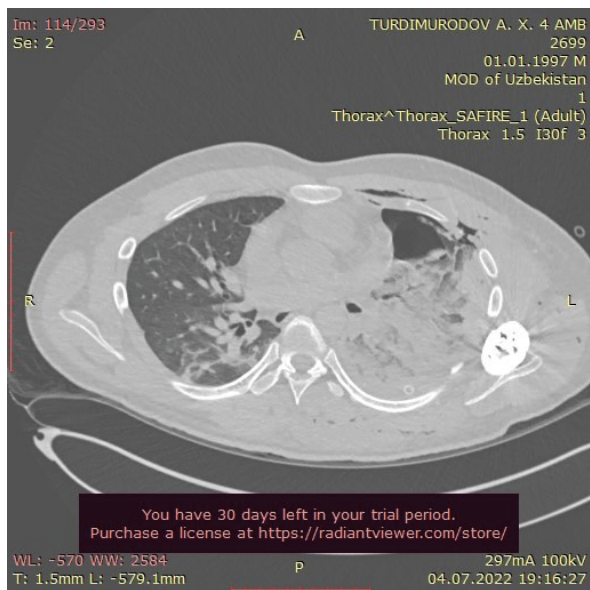


Fig.2.

Foreign body is indicated by an arrow

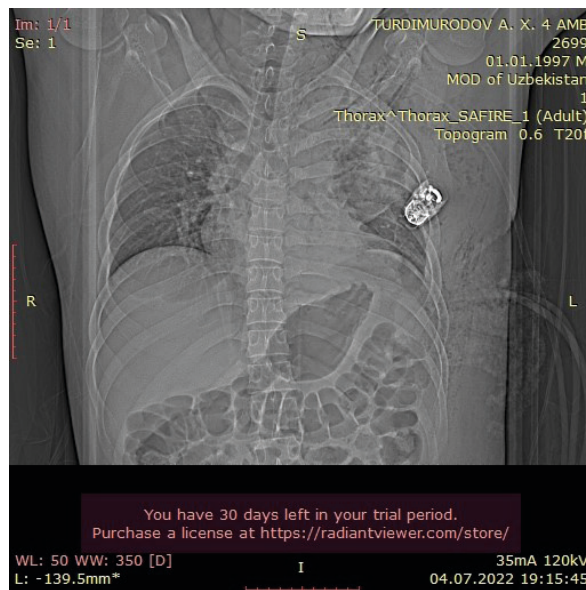


Fig.3.

Foreign body is indicated by an arrow

Body temperature reached to 39.40C, hemodynamics was unstable, blood pressure varied between 100/60 - 80/40 mmHg, pulse reached 140-150 per minute. From chest drains 150 ml of lysed blood per hour output during fourth day from injury day, black in color, with a specific odor, air was discharged through the drains, on the fifth day - 800 ml, on the 6-th day - 750 ml, on the 8th - 800 ml. There was no sealing of the pleural cavity, the amount of discharge through the drains did not decrease over time, but there were no obvious signs of ongoing intrapleural bleeding. In this regard, conservative tactics were followed, antibacterial therapy, symptomatic therapy, infusions, blood transfusions (fresh frozen plasma, albumin, red blood cells) were carried out. Repeated sanitation bronchoscopy was carried out, which revealed hyperemia and swelling of the mucous membrane of the trachea and main bronchi; there was blood in the lumen of the upper lobe bronchus on the left, which after sanitation did not show signs of ongoing pulmonary hemorrhage.

On the eighth day, at about 22:30, the patient experienced a sharp decrease in pressure to 65/30 mm Hg, about 800 ml of fresh blood comes through the pleural drainage in less than 40 minutes. The patient was taken for emergency surgery under general anesthesia. A rethoracotomy and

revision of the left pleural cavity were performed. During the inspection, a burn was noted throughout the left pleural cavity, the internal surfaces of the body of the ribs from the first to the seventh were exposed (Fig. 5), in these places the intercostal muscles had the color of boiled meat. There is about 400 ml of clotted blood in the pleural cavity. Diffuse mild bleeding is noted from the intercostal muscles and the upper lobe of the left lung. In the projection of segments 1-3 along the anterior surface there are three U-shaped sutures; air and blood enter through the wound on the lung. The left upper lobe, in the S1-2-3-4 projection, is airless, compacted, dark gray in color; multiple tissue defects in the form of cracks are noted on the surface of the lung and visceral pleura, from which blood and air flow. Left upper lobectomy was performed. The pleural cavity is drained by two silicone drains with a diameter of 28 Fr/Cl along the anterior and posterior surfaces of the mediastinum. The pleural cavity is washed with decasan solution. Drains for active aspiration with a vacuum of 30 cm of water column. A blood transfusion was performed with four packs of red blood cells up to 94 g/l. Histological examination of the macropreparation (Fig. 6) 1736-40: traumatic damage to the pulmonary parenchyma, obvious destructive-necrotic



Fig.4.

Removed foreign body of soft tissue of the left half of the chest (grenade fuse)

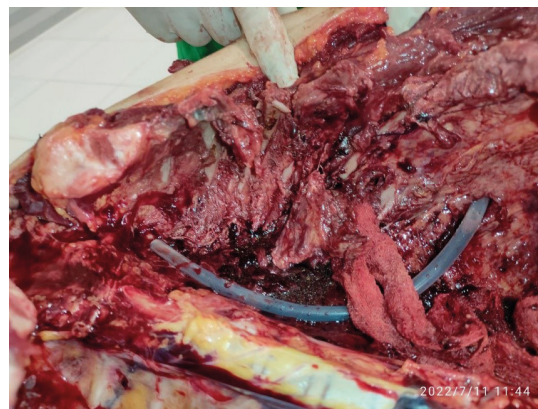


Fig. 5.

Exposed inner surfaces of the ribs on the left (autopsy)



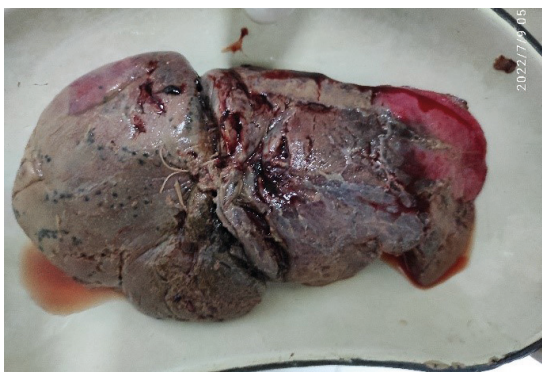

Fig. 6.  
Removed left upper lobe

changes in the pulmonary parenchyma in the area of damage, post-traumatic purulent-hemorrhagic pulmonitis, pronounced hemorrhagic inflammation of the perifocal areas, purulent-hemorrhagic inflammation in the places of interrupted sutures.

The pleural cavity was washed daily with 500 ml of decasan solution three times a day - the infusion was carried out by drip through the anterior drainage, the outflow was established through the rear drainage. Bandages were changed as they became dirty. On the tenth day, from 9:00 to 20:00 through the drainage, 400 ml of black hemorrhagic discharge, from 20:00 to 21:00 to 300 ml of fresh blood, from 21:00 to 22:00 100 ml of hemorrhagic

discharge. General blood tests showed hemoglobin 100 g/l, hematocrit 30.9%, red blood cells 3.43, platelets 75. Taking into account the general condition of the patient, it was decided to continue conservative therapy in the form of blood transfusion and hemostatic therapy. From 22:00 on the tenth day to 8:00 on the 9th day there was about 350 black hemolyzed discharge through the drains. At 8:00 on the 11th day, 1000 ml of fresh blood suddenly flowed through the drains, and breathing and heartbeat stopped. After resuscitation measures, the patient was pronounced dead at 8:30.

#### CONCLUSIONS

Despite the available modern equipment, the level of development of medicine today, gunshot wounds of the chest, both combat and non-lethal special means, and the damage they cause to organs and systems remain still unstudied. Based on this clinical example, we made the following conclusions:

- a blind gunshot wound to the chest with an extensive entrance wound should always alert the surgeon and he must first answer the following questions for himself: etiology, quantity and location of the wounding projectile, the nature of the wound channel and the extent of the lesion;
- the diagnostic tactics followed should answer the questions posed and help with the choice of the most correct and gentle method of surgical treatment;
- such isolated chest wounds from flash-noise grenades with a thermal-chemical burn of the pleural cavity caused a number of difficulties in establishing this fact and the correct choice of subsequent treatment.

#### ЛИТЕРАТУРА/REFERENCES:

1. Homenko IP, Korol' SO, Halik SV, et al. Clinical and epidemiological analysis of the structure of combat surgical trauma during the anti-terrorist operation/joint forces operation in Eastern Ukraine. *Ukr J Mil Med.* 2020;2:5-13. doi:10.46847/ujmm.2021.2(2)-005.
2. McIntyre J. Syrian Civil War: a systematic review of trauma casualty epidemiology. *BMJ Mil Health.* 2020;166(4):261-265.
3. Wichlas F, Hofmann V, Strada G, Deininger C. War surgery in Afghanistan: a model for mass casualties in terror attacks? *Int Orthop.* 2020;44(12):2521-2527.
4. Shnitko SN, Bisenkov LN. Current issues in diagnosis and treatment of gunshot chest wounds. *Voennaja Medicina.* 2007;1:84-91. (In Russ.)
5. Ivchenko DR. Surgical treatment of combined gunshot penetrating chest wounds in counter-terrorist operations [dissertation]. Moscow; 2020:1-49. (In Russ.)
6. Brjusov PG. Surgery of modern combat chest trauma. *Voенно-медицинский Журнал.* 2010;331(1):20-28. (In Russ.)
7. Brjusov PG, Urazovskij NJu. New technologies in the surgical treatment of gunshot penetrating chest wounds. *Hirurgija.* 2001;3:46-51. (In Russ.)
8. Senanayake EL, Poon H, Graham TR, Midwinter MJ. UK specialist cardiothoracic management of thoracic injuries in military casualties sustained in the wars in Iraq and Afghanistan. *Eur J Cardio-Thorac Surg.* 2014;45(6):202-3207.
9. Homenko IP, Gerzhik KP, Kucher BM. The place and role of video-assisted thoracoscopic surgery in combat injuries and chest organ trauma. *Visnyk Vinnytsia Natl Med Univ.* 2018;22(3):522-524.
10. Voskresenskij OV. Criteria for the safe performance of thoracoscopy in patients with chest wounds. *Zh Im NV Sklifosovskogo Neotlozhnaja Med Pomoshh.* 2015;1:33-37. (In Russ.)

Received 10.04.2024; reviewed 05.06.2024; accepted for publication 17.06.2024.

Author information: Babur Zh. Usmanov — Senior Resident, Thoracic Surgery Department, Central Military Clinical Hospital, Ministry of Defense, Republic of Uzbekistan. E-mail: usmbabur@gmail.com

Authors' contribution: Usmanov BZh — study concept, data collection, manuscript writing.

Funding: The work had no specific funding.

Conflict of interest: The authors declare no explicit and potential conflicts of interest associated with the publication of this article.

Статья поступила 10.04.2024; одобрена после рецензирования 05.06.2024; принята к публикации 17.06.2024.

Информация об авторах: Усманов Бабура Женисбай улы — старший ординатор отделения торакальной хирургии Центрального военного клинического госпиталя Министерства Обороны Республики Узбекистан. E-mail: usmbabur@gmail.com

Вклад авторов: Усманов Б.Ж. — концепция исследования, сбор данных, написание текста рукописи.

Источники финансирования: Работа не имела специального финансирования.

Конфликт интересов: Авторы декларируют отсутствие явных и потенциальных конфликтов интересов, связанных с публикацией настоящей статьи.