

SURGICAL TREATMENT OF MUCOCOLPOS BY PRESERVING THE HYMENAL RING**B. B. Negmadjanov, F. I. Zokirov, E. Kh. Shopulatov**
Samarkand state medical university, Samarkand, Uzbekistan**Key words:** hymen, imperforate hymen, mucocolpos, hymenal ring.**Tayanch soʻzlar:** qizlik parda, qizlik parda atreziyasi, mukokolpos, qizlik parda xalqasi.**Ключевые слова:** девственная плева, атрезия гимена, мукокольпос, гименальное кольцо.

Imperforate hymen is a rare common congenital anomaly of the female genital tract, in which the hymen completely closes the entrance to the vagina. Despite the fact that the diagnosis of this pathology is not difficult, often when examining a newborn by a neonatologist immediately after childbirth, this pathology remains undiagnosed. In the neonatal period, under the influence of maternal estrogen, the glands of the newborn's vagina secrete mucus, due to the accumulation of which in imperforate hymen mucocolpos develops. The latter causes a pronounced pain syndrome, up to ischuria. This article highlights the method of surgical treatment of mucocolpos with the preservation of the hymenal ring in 21 girls aged 4.5 months to 2.4 years. With this method, there is no need to approximate mucosal margins to prevent reclosure of hymenal orifice which potentially preserves the integrity of the hymenal ring.

MUKOKOLPOSNING QIZLIK PARDA XALQASINI BUZMAYDIGAN JARROHLIK DAVOLASH USULI**B. B. Negmadjanov, F. I. Zokirov, E. X. Shopulatov**

Samarqand davlat tibbiyot universiteti, Samarqand, O'zbekiston

Qizlik parda atreziyasi qiz bolalarda uchrab turadigan jinsiy a'zolarining tug'ma nuqsoni bo'lib, bunda qizlik parda qinning kirish qismini butunlay yopib quyadi. Bu patologiyani tashxislash murakkab emasligiga qaramay, u chaqaloq tug'ilganidan so'ng neonatolog tomonidan ko'rikdan o'tkazilganda ko'pincha e'tibordan chetda qoladi. Neonatal davrda ona sutidagi estrogenlar ta'sirida qin bezlari shilliqli ajralmalar ishlab chiqaradi va qizlik parda atreziyasida bu shilliqli ajralmalar qinda to'planib qolib mukokolposning rivojlanishiga olib keladi. Mukokolpos esa o'z navbatida kuchli og'riqli sindrom va hatto ishuriyaning rivojlanishiga sabab bo'ladi. Mazkur maqolada 4,5 oylikdan 2,4 yoshgacha bo'lgan 21 nafar qizchalarda mukokolposning qizlik parda xalqasini saqlaydigan jarrohlik davolash usuli haqida ma'lumotlar yoritilgan. Bu jarrohlik usulida qizlik pardaning qayta yopilishining oldini olish uchun shilliq qavatga qo'shimcha choklar qo'yish zaruriyati yo'qligi natijasida qizlik parda xalqasining butunligi saqlanadi.

МЕТОД ХИРУРГИЧЕСКОГО ЛЕЧЕНИЯ МУКОКОЛЬПОСА С ПРЕЗЕРВАЦИЕЙ ГИМЕНАЛЬНОГО КОЛЬЦА**Б. Б. Негмаджанов, Ф. И. Зокиров, Э. Х. Шопулатов**

Самаркандский государственный медицинский университет, Самарканд, Узбекистан

Атрезия гимена является редко встречающейся врожденной аномалией женских половых органов при которой девственная плева полностью закрывает вход во влагалище. Несмотря на то что диагностика данной патологии является не сложной, нередко при осмотре новорожденной неонатологом сразу после родов данная патология остается незамеченным. В неонатальном периоде под воздействием материнского эстрогена железы влагалища новорожденной секретируют слизь, вследствие накопления которой при атрезии гимена развивается мукокольпос. Последний вызывает выраженный болевой синдром, вплоть до ишурии. В данной статье освещен метод хирургического лечения мукокольпоса с презервацией гименального кольца у 21 девочек в возрасте от 4,5 месяцев до 2,4 года. При данном методе нет необходимости наложения дополнительных швов на края плевы для предупреждения повторного зарращения, что дает возможность сохранения целостности гименального кольца.

Introduction: Imperforate hymen is a rare congenital anomaly of the female genital tract in which the hymen completely closes the entrance to the vagina. Hymen serves as a boundary between internal and external genitalia. It is formed by the proliferation of the sinovaginal bulbs, perforation of which occurs before or after birth. [4,6,10]. Imperforate hymen occurs when perforation of these tissue or its canalization fails to occur and it is at the extreme of a spectrum of various configurations of hymen such as fenestrations, septa, bands, microperforations, anterior displacement, and differences in rigidity and/or elasticity of the hymenal tissue. [2,4,6].

As a most common form of congenital outflow obstruction it is seen in 0,05-0,1% of female neonates [4,10]. Despite the thorough examining of a newborn by a neonatologist immediately after birth, it commonly escapes diagnosis until the time of menarche.

In the neonatal period, under the influence of maternal estrogen, the glands of the vagina of

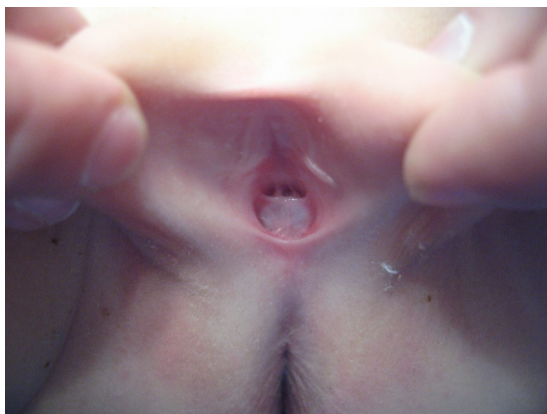

Fig. 1. Patient with mucocolpos in lithotomic position

the newborn secrete mucus, due to the retention of which, mucocolpos develops (Fig. 1.) [2,3,10]. In this cases patients usually brought to pediatric emergency services with presentation of a pronounced pain syndrome, up to ischuria. Also a treatment of imperforate hymen is a simple surgical procedure, in which after an incision on hymenal tissue and evacuation of accumulated secrete, edges of incised hymenal tag are sutured to achieve complete hemostasis and prevent reclosure [4,11]. Suturing the edges of hymenal tag often damages the integrity of hymenal ring. Taking into account the cultural concerns regarding virginity, hymen preserving techniques are of relevance in some cultures.

Objective: Objective of our study was to determine the outcomes of hymen preserving surgical technique in treatment of 20 girls with mucocolpos.

Material and methods: A total of 20 girls at the age between 4.5 months and 2.4 years (mean age 4.0 months) were included into the study at the department of pediatric gynecology of Samarkand Regional Multidisciplinary Children’s Medical Centre between 2008 and 2016. 14 girls out of 20 were presented with signs of disturbance like poor sleep, crying while voiding, frequent urination (dysuria). All of them primarily attended a pediatrician and were subscribed conservative symptomatic treatment. The effect was temporary, after long cyclic symptomatic treatment, during hygienic procedures parents noticed a mass in the external genital area. 6 of 20 patients presented with a presence of a mass in the external genital area occasionally found during hygienic procedures by parents with no symptoms. In 2 patients out of 6 previously mucocolpos was diagnosed and routine puncture and drainage of mucocolpos was performed. They presented with recurrence of mucocolpos.

All patients except general clinical investigations in which by visual inspection mucocolpos was diagnosed, were undergone ultrasonic examination in which diagnosis was confirmed. In gynecological examination bulging of hymenal tag with yellow-grayish color protruding with the Valsalva maneuver was determined.

First of all, parents of patients were informed about classical surgical methods of treatment, but they usually opted for preservation of hymenal ring as much as possible.

After appropriate preparations and informed consent under general anesthesia patients were positioned in the lithotomy, adequate access was provided. After catheterization of urethra to identify the latter by monopolar electrocautery by the course of hymenal ring central part of hymenal tag was resected (Fig. 2.).

Then drainage of mucus retained and subsequent irrigation with 3% solution of hydrogen peroxide and saline solution were performed (Fig. 3.).

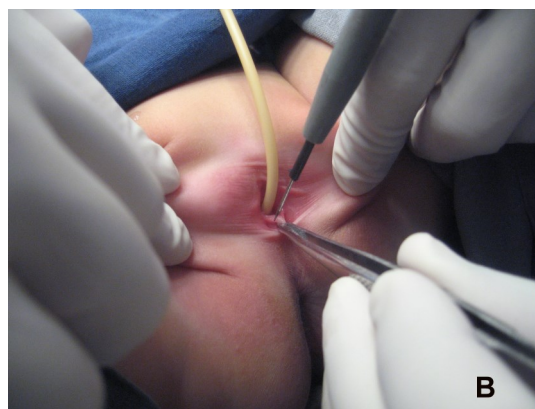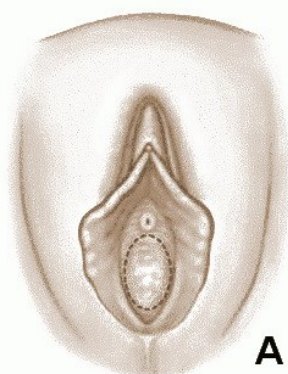


Fig. 2. Schematic (A) representation (dotted line) of the course of incision on hymenal tissue to preserve the hymenal ring and during surgery (B).

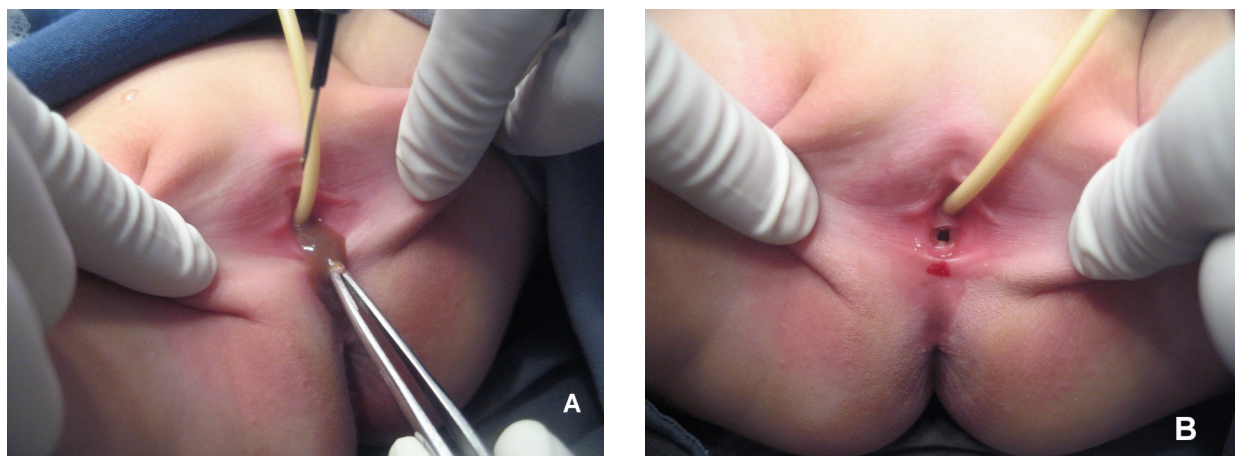


Fig. 3. Drainage of retained mucus after resection of hymenal tissue (A) and view of hymen immediately after surgery (B).

No prophylactic antibiotic was administered except 2 patients whom previously routine puncture and drainage of mucocolpos was performed.

In postoperative period external genitalia twice a day were treated with antiseptic solutions.

Results: The course of postoperation was uneventful and on third day after control examination of hymen patients in a good condition were discharged from hospital. In control examination hymenal structure was found to be annular and created hymenal orifice remained open, no signs of inflammation or infection were revealed. Before discharge parents were warned about the risks of infection and we advised them to keep vulva clean and dry. Next control examination was performed in 1 month in which hymenal pattern was same as before discharge. Complications such as infection and reclosure were not detected in any cases.

Discussion and conclusion: Imperforate hymen is likely the most frequent congenital outflow obstruction anomaly of the female genital tract and estimates of its frequency vary from 1 case per 1000 population to 1 case per 10,000 populations [4,6]. Management of an imperforate hymen has remained unchanged from the initial descriptions of the procedure. In the classical surgical treatment of imperforate hymen, stellate or cruciate incisions are made on the hymenal tag. The quadrants of the incised hymen are then excised along the lateral wall of the vagina. The mucosal margins are approximated with fine delayed-absorbable suture [11]. These technique have good surgical outcome, but the hymenal structure is usually damaged. In addition, injury to the adjacent urethra is possible [5,7,9].

Various management approaches have been recommended, such as the use of laser or electrosurgery instead of a scalpel to excise the hymenal tag, but for various reasons these recommendations have not been widely adopted in practice.

Due to the hymen is accepted as a sign of virginity, damage to the hymen may be undesirable in some societies as well as in Uzbekistan and it is important to preserve the annular structure of the hymen in gynecological practice.

In literature there are some reports of hymen sparing surgical treatments of imperforate hymen. In a study of A. Acar et al. (2007) women with imperforate hymen were surgically treated by a central incision of hymen and application of Foley catheter for two weeks. They report good surgical outcome and no known complication of their method. But their method is so uncomfortable especially for such young girls who have to carry foreign material (Foley catheter) protruding from the vagina for two weeks [1].

A case report of O. Temizkan et al. (2012) also deserves interests. They used a small central hymenotomy under general anesthesia and subsequent evacuation of retained blood in two girls with imperforate hymen and hematometocolpos. They also report good surgical outcome and no known complication of their method. But the result of two cases is not sufficient to provide a conclusion [12].

Thus we can conclude that there is no known complication of this method and study similar

to this was not reported in the literature especially in infants in whom surgery area is very small. As being less invasive than other methods, there is no need to approximate mucosal margins to prevent reclosure of hymenal orifice which potentially preserves the integrity of the hymenal ring.

References:

1. Acar A, Balci O, Karatayli R, Capar M, Colakoglu M. The treatment of 65 women with imperforate hymen by a central incision and application of Foley catheter. *BJOG* 2007;114:1376–1379.
2. Gynecologic Examination for Adolescents in the Pediatric Office Setting Paula K. Braverman, Lesley Breech and The Committee on Adolescence. *Pediatrics* 2010;126:583. DOI: 10.1542/peds.2010-1564.
3. Hewitt G. Examining pediatric and adolescent gynecology patients. *J Pediatr Adolesc Gynecol.* Aug 2003;16(4):257-8. [Medline].
4. Imperforate Hymen. Paula J Adams Hillard, 2016. <https://emedicine.medscape.com/article/269050-overview#a8>
5. John AR. Surgical conditions of the vagina and the urethra. In: Thompson JD, Rock JA, editors. *Te Linde's Operative Gynecology*, 7th edn. Philadelphia, PA: Lippincott Company; 1992. pp. 1125–40.
6. Lee, G.H.; Lee, M.J.; Choi, Y.S.; Shin, J.I. Imperforate hymen causing hematocolpos and acute urinary retention in a 14-year-old adolescent. *Child. Kidney Dis.* 2015, 19, 180–183.
7. Letts M, Haasbeck J. Hematocolpos as a cause of back pain in premenarchal adolescents. *J Pediatr Orthop* 1990;10:731–2.
8. Mou, J.W.; Tang, P.M.; Chan, K.W.; Tam, Y.H.; Lee, K.H. Imperforate hymen: Cause of lower abdominal pain in teenage girls. *Singap. Med. J.* 2009, 50, 378–379.
9. Muram D. Pediatric and adolescent gynecology. In: Pernoll ML, editor. *Current Obstetric and Gynecologic Diagnosis and Treatment*, 7th edn. East Norwalk, CT: Appleton and Lange; 1991. pp. 629–56.
10. Pediatric Imperforate Hymen, Amulya K Saxena and co. 2018. <https://emedicine.medscape.com/article/954252-overview#showall>
11. *Te Linde's Operative Gynecology*, 10th Edition. John A. Rock, Howard W. Jones. Lippincott Williams & Wilkins. 2008.
12. Temizkan O, Kabil Kucur S, Agar S, Gözü'kara I, Akyol A, Davas I. Virginity sparing surgery for imperforate hymen: report of two cases and review of literature. *J Turk Ger Gynecol Assoc* 2012;13:278-280.